Journal of Surgery
[Jurnalul de Chirurgie]

Case Report Open Access

Rare discovery in young woman- Hernia and Chyst of Canal Nuck

Catalina Roxana Chiriac, Ana-MariaTrofin, Mihai Lucian Zabara, Ramona Cadar, Veaceslav Costin, Ioannis Kakavas, Felicia Crumpei, Corina Ursulescu-Lupascu, Andreea Ludusanu, Cristian Lupascu
First Surgical Clinic, "St. Spiridon" Hospital, Iaşi

Abstract
Rare causes of inguinal region swelling in adult women are hernias and cysts of canal Nuck. Canal Nuck hernia's is defined by the processus vaginalis deficiency of closure during intrauterine development in female foetuses, where the parietal peritoneum persists opened through the inguinal canal to the labia majora after birth (1,2). Optimal therapeutic choice is surgery if the diagnosis of hernia is established (3). The case presented below is of right sided cyst of canal of Nuck with right inguino-labial hernia in a 46 years old female.

Keywords: chyst, canal Nuck, hernia

Introduction

The Canal of Nuck was first discovered and publicated in literature 1691 by Anton Nuck (4). It represents the small evagination of the parietal peritoneum that elongates through the inguinal canal to labia majora. Is considered the female analogue of the processus vaginalis in males which closes in early life stages (5,6). On exceptional occasions the defect persists in adult women and generates associated pathologies such as uncomplicated or complicated hernias, cysts and hydrocele (7).

Case report

A 46-years old female presented in our department with swelling in the right inguinal region associated with pain. The symptoms developed during the past six months with gradual increasing in size. Patient's medical history was negative for trauma, abdominal discomfort, nausea or vomiting, and no chronic diseases or surgical procedures were reported. She had uncomplicated vaginal deliveries and regulated menstrual cycle.

Clinical examination revealed body mass index was 22 kg/m2, soft, non-tendered, non-distended abdomen, with no sign of bowel occlusion. The right inguinal region had a palpable, mobile lump without skin colour modification, no induration and no erythema. On Valsava maneuver the mass became more proeminent indicating an inguinal hernia. No signs of incarceration or strangulation were observed.

Laboratory tests (complete blood count, urinalysis, blood biochemistry) were within normal range. Soft tissue ultrasonography revealed a hypoechoic cystic mass, 80 x 42 x 68 mm in size and 122,62 ml in volume, located in the right inguinal area without any vascular flow and no peristalsis (fig. 1).

*Corresponding author: Ana-MariaTrofin, e-mail: ana-maria.trofin@umfiasi.ro
Received July 19, 2021; Accepted September 15, 2021; Published September 30, 2021
Citation: Chiriac,Catalina Roxana, Trofin Ana-Maria, Zabara M.L., Cadar Ramona, Costin V., Kakavas I., Crumpei Felicia, Ursulescu-Lupascu Corina, Lupascu Cr.: Rare discovery in young woman- Hernia and Chyst of Canal Nuck. Journal of Surgery [Jurnalul de chirurgie]. 2021; 17(3): 206 - 209. [Article in Romanian]. DOI:10.7438/JSURG.2021.03.07

Copyright: © 2020 Chiriac,Catalina Roxana et al. This is an open-access article distributed under the terms of the Creative Commons Attribution License, which permits unrestricted use, distribution, and reproduction in any medium, provided the original author and source are credited

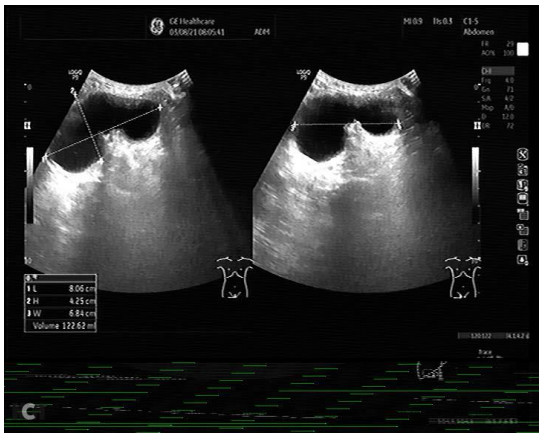

Fig. 1 Ultrasound of the right groin

We performed surgical exploration by inguinotomy that revealed a hernia with the content of a polilobular cyst, aproximately 10 cm in size (fig. 2).

We continued with the dissection and excision of the cyst from the round ligament and closure of the inguinal ring by an anterior approach. The defect was repaired with prolene mesh. Postoperative course was uneventful, without any complications and the patient was discharged two days after surgery.

The surgical specimen was sent for histopathological analysis which reported:

- Macroscopic:
  Cystic mass of 10,3/4/1,5 cm, with smooth, shiny external surface, slim walls, with the internal content of serous citrine fluid.
- Microscopic:
  Conjunctival-vascular-adipose tissue with matters of stasis.
  The patient had favorable post-operative outcome.

Discussion

Canal of Nuck in adult women is a scarce congenital entity represented by the everting of the parietal peritoneum which accompanies the round ligament of the uterus through the inguinal ring into the inguinal canal (8). Hernia, cysts and hydrocele are the most frequent conditions associated with it.

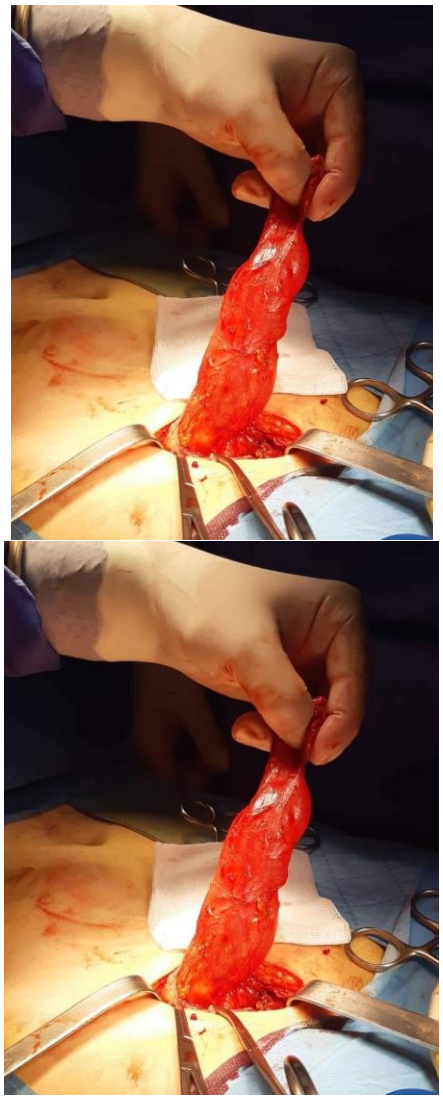

Fig. 2 Intraoperative finding: Cystic mass at the right inguinal region.

Symptoms related to Canal of Nuck hernias are pelvic or groin pain, inguinal or inguino-labial swelling and tenderness, without erythema, induration or skin colour variation. (9) Valsava maneuver is the physical exam easy to perform for appreciating an existing hernia. (10)
In many situations the cyst of the Canal of Nuck is misdiagnosed as inguinal hernia therefore the mass is often confirmed during surgery. In the above case we established the

diagnose of inguinal hernia from the moment we physical examed the female in outpatient room. Proceeding with the echography we suspected a cyst of Canal Nuck. After surgery we found both to be true.

In terms of preoperative imaging investigations such as CT, MRI are mandatory to establish the correct diagnosis and to be able to choose the accurate treatment. Furthermore ultrasonography is a fast, cheap, non-invasive imaging procedure but not always conclusive. When is required it should be correlated with other imaging examinations.

A hernia and cyst of the canal of Nuck treatment requires always surgery that can take into account open or laparoscopic excision of the cyst and closure of the the inguinal weakness. The correct surgical approach is assessed according to several factors such as the accuracy of preoperative diagnosis, the extent of the pathologhy, the co-existence of an inguinal hernia and it's dimensions. Laparoscopic excision is indicated when the mass is small and proximal to the inguinal ring.

Conclusions

Canal of Nuck pathology in adult women is a very rare condition, seldomly mentioned in literature. It should be taken into consideration as a differential diagnosis in females with inguino-labial swellings.

A soft tissue ultrasonography should be a routine investigation performed on patients with groin swellings and, when necessary, it should be followed up with more detailed imaging exams.

The gold standard treatment of canal of Nuck cyst and hernia is surgery. There are two techniques to proceed with laparoscopic or opened surgery.

Disclosure:

The authors have nothing to disclose.

Patient consent:

The patient consent was obtained.

References

1. O'Rahilly R, Muller F (1992) Human embryology and teratology. Wiley-Liss, New York, pp 219-221
2. Shadbolt C.L, Heinze S.B, Dietrich R.B Imaging of groin masses: inguinal anatomy and pathologic conditions revisited. Radiographics. 2001; ([21 Spec No]): S261-S271
3. Bhosale P.R. et al. The inguinal canal: anatomy and imaging features of common and uncommon masses. Radiographics. 2008; 28 ([quiz 913]): 819-835
4. Nuck, Anton (1691). "De Peritonaei Diverticulis Novis" [The new Peritone Diverticulitis]. Adenographia curiosa et uteri foeminei anatome nova [Curious and of the womb of the female anatomy a new Adenographia] (in Latin). Leiden. pp. 130–8.
5. Nasser H, King M, Rosenberg HK, et al. Anatomy and pathology of the canal of Nuck. Clin Imaging 2018; 51:83–92.
6. Jedrzejewski G, Osemlak P, Wieczorek AP, et al. Nuck canal hernias, typical and unusual ultrasound findings. Ultrasound Q 2019; 35:79–81.
7. Zawaideh JP, Trambaiolo Antonelli C, Massarotti C, Remorgida V, Derchi LE. Cyst of Nuck: A disregarded pathology. J Minim Invasive Gynecol. 2018;25:376–377. doi: 10.1016/j.jmig.2017.08.003.
8. Caviezel A, Montet X, Schwartz J, Egger JF, Iselin CE. Female hydrocele: The cyst of Nuck. Urol Int 2009;82:242-5

9. Dagur G, Gandhi J, Suh Y, Weissbart S, Sheynkin YR, Smith NL, Joshi G and Khan SA: Classifying hydroceles of the pelvis and groin: An overview of etiology, secondary complications, evaluation, and management. Curr Urol 10: 1-14, 2017
10. De Meulder F, Wojciechowski M, Hubens G, et al. Female hydrocele of the canal of Nuck: a case report. Eur J Pediatr 2006; 165:193–194