

Acute Generalized Exanthematous Pustulosis in a 51-Year-Old Patient under Etanercept Treatment for Psoriasis

Luciana Mabel Ferreira Vasconcelos¹, Fabricia Martins Teixeira², Eudiana Vale Francelino³, Thereza Lucia Prata Almeida⁴, Larissa Bomfim Chagas⁴, Jose Telmo Valença Jr⁵ and Aparecida Tiemi Nagao-Dias^{6*}

¹Posgraduation Program of Pharmaceutical Sciences, Faculty of Pharmacy, Federal University of Ceara (UFC), Brazil

²Central Public Health Laboratory (LACEN), Ceara, Brazil

³Faculty of Pharmacy, Pharmacovigilance Center of Ceara, UFC, Brazil

⁴Department of Dermatology, Hospital Universitário Walter Cantídio, UFC, Brazil

⁵Faculty of Medicine, Department of Pathology, UFC, Brazil

⁶Faculty of Pharmacy, Department of Clinical Analysis and Toxicology, UFC, Brazil

Abstract

Acute generalized exanthematous pustulosis (AGEP) is a cutaneous reaction mostly related to drug, which is characterized by a rapid appearance of fever, erythema, sterile pustules and neutrophilia. We report a 51-year-old female patient who had taken etanercept 50 mg/week for treatment of psoriasis. In the third month of pharmacotherapy, she interrupted the treatment on her own, and consequently, the lesions reappeared. When the drug was reintroduced, it was associated with prednisone 40 mg/day during 5 days. After this period, multiple erythematous and edematous lesions appeared with small non-follicular pustules. Oral corticosteroid was administered and a progressive and complete improvement was achieved. Histopathological findings revealed AGEP. Bacterioscopy of the pustules proved negative. The patient obtained the score 12 according to the EuroSCAR study group, which indicated a definitive diagnosis of AGEP. The criteria for diagnosis were based on morphology, course and histology of the skin reaction. The association between Etanercept and AGEP is an uncommon finding in the literature.

Keywords: Etanercept; Acute generalized exanthematous pustulosis; Adverse drug reaction

Introduction

Etanercept is a soluble TNF- α antagonist approved by the United States Food and Drug Administration for treatment of psoriasis, psoriatic arthritis, rheumatoid arthritis, juvenile idiopathic arthritis and ankylosing spondylitis [1]. Acute generalized exanthematous pustulosis (AGEP) is a significant adverse cutaneous reaction [2] characterized by the presence of multiple disseminated sterile pustules located sub-corneally in the epidermis associated with fever, massive neutrophilia and sometimes, eosinophilia [3]. This reaction pattern is most often described in association with drugs (90%), acute viral infections, spider bites and heavy metals. The involvement of drug-specific T cells in the pathomechanism can be confirmed by positive skin patch tests and lymphocyte transformation tests [2].

Some adverse events related to anti-TNF- α are injection site reaction, drug-induced lupus erythematosus, infuse reactions, vasculitis [4] and secondary infections such as tuberculosis, leprosy, histoplasmosis, coccidioidomycosis and aspergillosis [5]. Cutaneous adverse reactions associated with etanercept include psoriasis form skin reactions [6], generalized exanthema [7], lupus erythematosus-like syndrome [8], leukocytoclastic vasculitis [9] and erythema multiforme [10]. The association between etanercept and AGEP is very uncommon and until now only 1 case has been described in the literature [11]. We report a 51-year-old female patient who had taken etanercept 50 mg/week for treatment of psoriasis and subsequently developed AGEP.

Case Report

A 51-year-old woman from the state of Ceara, Brazil, with refractory erythrodermic psoriasis and psoriatic arthritis was treated with **infliximab in the period from 2008 to February 2010** (infusions of 5 mg/kg at week 0, 2, and 6 and then every 8 weeks) in association with methotrexate (7.5 mg/wk orally). By the fact the patient did not respond to the therapy, treatment with infliximab was discontinued

and monotherapy with etanercept (**50 mg twice/wk**) was initiated in February 2010. Thereafter, in April 2010, the patient interrupted the treatment on her own, with consequent relapse of psoriatic lesions. In May 2010, the etanercept treatment was restarted (50 mg/wk) coupled with prednisone (40 mg/day for 5 days). In June 2010, she presented eruption with non-follicular sterile pustules on a diffuse, edematous erythema accompanied by fever above 38°C. The treatment with etanercept was suspended. The skin lesions began on the face and intertriginous regions, moving to trunk and lower limbs, and showed a characteristic post-pustular desquamation after few days (Figures 1A and 1B).

Ciprofloxacin 500 mg three times a day was prescribed before her admission at the hospital. After the patient was hospitalized, the treatment was replaced by cephalotin 3 g/day, and after by ceftriaxone 2 g/day. It was supposed that psoriasis had worsened and that she got a secondary infection. Bacterioscopy of the pustules proved negative. The patient experienced fever spikes, chills, hyporexia, edema of the face, upper and lower limbs, and exfoliative erythroderma, which affected the dorsum of hands and feet. Laboratorial parameters on her admission revealed the following results: white blood cell counts $1.16 \times 10^3/\text{mm}^3$ (4.0 to $10.0 \times 10^3/\text{mm}^3$), neutrophils 85% (42.2-75.2%),

***Corresponding author:** Aparecida Tiemi Nagao-Dias, Faculty of Pharmacy, Department of Clinical Analysis and Toxicology, Federal University of Ceara, Rua Capitao Francisco Pedro, 1210, CEP 60430-370, Fortaleza, Ceara, Brazil, Tel: 55-85-3366-8270; Fax: 55-85-3366-8292; E-mail: tiemindi@yahoo.com.br

Received November 06, 2013; **Accepted** February 04, 2014; **Published** February 11, 2014

Citation: Vasconcelos LMF, Teixeira FM, Francelino EV, Almeida TLP, Chagas LB, et al. (2014) Acute Generalized Exanthematous Pustulosis in a 51-Year-Old Patient under Etanercept Treatment for Psoriasis. J Pharmacovigilance 2: 120. doi:10.4172/2329-6887.1000120

Copyright: © 2014 Vasconcelos LMF, et al., This is an open-access article distributed under the terms of the Creative Commons Attribution License, which permits unrestricted use, distribution, and reproduction in any medium, provided the original author and source are credited.

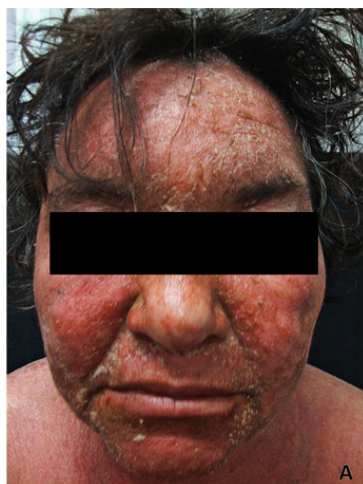

Figure 1a: A 51-year old woman with AGEP caused by etanercept. The patient presented edematous erythema on the face with perioral pustules.

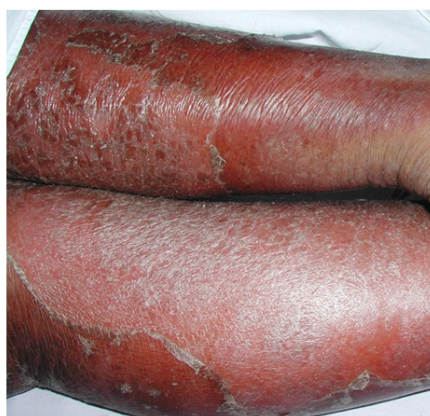

Figure 1b: The lesions progressed to trunk and limbs. A diffuse erythema and swelling, showing a characteristic postpustular desquamation was observed after few days in the lower limbs.

eosinophils 6% (0-10%) and erythrocyte sedimentation rate 70 mm/hour (0-30 mm/hr).

On hospital day 11, the patient complained of nocturnal dyspnea, hypoxia and exacerbation of edema of the upper and lower limbs. Respiratory auscultation revealed pulmonary crackles, wheezing, breathing and tachypnea (respiratory rate: 36 ipm). Chest X ray showed pulmonary congestion. A single dose of furosemide 40 mg injected intravenously followed by 20 mg orally every 8 hours was prescribed.

On hospital day 15, the patient had an episode of acute respiratory failure with decreased breath sounds, **tachypnea** (36 breaths/min) and cyanosis. The patient was stabilized by oxygen therapy and diuretics, bronchodilator and steroids administration. After, antibiotics were administered intravenously (piperacillin 4 g and tazobactam 0.5 g three times per day and teicoplanin 400 mg once daily). Culture of lung fluid revealed extended spectrum beta-lactamase *Klebsiella pneumoniae*.

On hospital day 16, the patient was transferred to the intensive care unit with severe sepsis, acute respiratory failure and pulmonary edema. The patient presented fever, anasarca, generalized scaling and

desquamation. After, she developed significant oliguria (100 mL/24h), requiring a larger input of intravenous hydration. The patient developed acute renal failure (creatinine concentration 2.8 mg/dl, serum urea concentration 79 mg/dl) and oliguria (200-450 mL/24h). Dialysis was required. Doppler echocardiography showed moderate systolic and mild diastolic dysfunction, and moderate anterior septal hypokinesia. At this time, the pustules were resolved spontaneously.

On hospital day 22, the combination piperacillin-tazobactam was replaced by meropenem 1 g per day. On day 25, the patient showed slight improvement in the general condition, full consciousness, afebrile, and spontaneous breathing. Nonetheless, the patient remained edematous and anuric (serum creatinine concentration 1.7 mg/dl, serum urea concentration 36 mg/dl). Furosemide 40 mg injected intravenously every 8 hours associated with prednisone 70 mg per day was prescribed. After one month of hospitalization, the patient experienced worsening of the psoriatic lesions with disseminated erythematous, crusted plaques on her legs and lamellar lesions on plantar surfaces. She also presented hyperglycemic peaks, lower limb edema, fever and dyspnea. The patient received oral corticosteroids (prednisone 40 mg per day), intravenous corticosteroids (hydrocortisone 300 mg), topical lotion Lanette, furosemide 40 mg intravenously and powerful antibiotics (teicoplanin 400 mg twice/ day, piperacillin 2.0 and tazobactam 0.25 g, four times per day, and meropenem 1g per day). The patient underwent nebulization with bronchodilators and Venturi mask adjuvant oxygen therapy.

In the following days, the patient became afebrile, with resolution of acute respiratory failure. She showed normal respiratory rates and a heart rate around 100 beats per minute. Lower limb edema resolved and the 24-hour diuresis volume normalized. The patient recovered from sepsis. Hemoculture and catheter tip culture were negative. Meropenem and teicoplanin were discontinued after 14 and 21 days, respectively.

The skin lesion biopsy revealed spongiform and intraepidermal subcorneal pustules with papillary edema, intraepithelial collections of neutrophils in the epidermis and lymphomononuclear infiltrates with eosinophil in superficial dermis (Figure 2).

We determined the likelihood of AGEP by use of the *European*

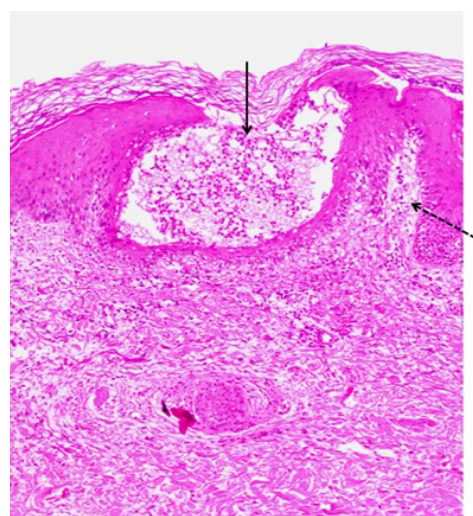


Figure 2: Histopathological analysis of skin biopsy (HE, 400x) showing an intraepidermal pustule containing neutrophils (continuous arrow) with papillary edema (dashed arrow).

Criteria	Description	Score
Morphology		
Pustules	Typical, non-follicular and sterile	+2
Erythema	Typical, diffuse	+2
Distribution/pattern	face, intertriginous areas, trunk and limbs	+2
Post-pustular desquamation	Yes	+1
Total score		+7
Course		
Mucosal involvement	No	0
Acute onset	Yes (few hours)	0
Resolution of pustules and erythema ≤ 15 days	Yes (~ 15 days)	0
Fever (≥ 38°C)	Yes (38.8°C)	+1
Blood neutrophil count (≥ 7000 cells/mm ³)	Yes (13600/mm ³)	+1
Total score		+2
Histopathological analysis		
Skin lesions	Spongiform sub corneal and intraepidermal pustules with papillary edema	+3
Total score		+3
Overall score		+12

Note: EuroSCAR= European project dedicated to severe cutaneous adverse reactions. Interpretation: score ≤ 0 indicates no AGE; 1 to 4 indicates possible AGE; 5 to 7 indicates probable AGE; and 8 to 12 indicates definitive AGE.

Table 1: Scoring system of the Euro SCAR study group for acute generalized exanthematous pustulosis [14]. The scores obtained by the patient are indicated in the last column.

project dedicated to severe cutaneous adverse reactions (EuroSCAR) study group's scoring system [3]. The criteria for AGE diagnosis were based on morphology, course and histology of the skin reaction (Table 1). Our patient obtained the score 12, which indicated a definitive diagnosis of AGE. Besides the typical clinical picture, the short course of the reaction was an important clue and one of the major parameters for the AGE validation score.

The causality assessment by Naranjo's algorithm [12] revealed a score +5 suggesting a probable adverse drug reaction (ADR) to etanercept. The Naranjo scale is a questionnaire for determining the likelihood of whether an ADR is actually due to the drug. The ADR is assigned to a probability category from the total score as follows: *definite* if the overall score is 9 or greater, *probable* for a score of 5-8, *possible* for 1-4 and *doubtful* if the score is 0. We considered the following aspects: a) the adverse event occurred after etanercept administration (score: +2); b) the adverse reaction improved when the drug was discontinued (score: +1); c) the patient was receiving etanercept monotherapy when the first symptoms of the adverse reaction occurred (score: +2).

The patient was patch-tested with etanercept (Enbrel, New Jersey, United States) 18 months after clinical resolution, according to the procedure done by Seneschal et al. [6]. The anti-TNF agent was diluted in 30% petroleum jelly, and the test was read after 48 hours and on the day 7. The preservatives, color agents and excipients were not tested because they are infrequent causes of delayed cutaneous drug adverse reactions and by the fact they were not available to be tested [13]. The results of patch testing were negative. It is necessary to remind that the patient was under use of adalimumab 40 mg subcutaneous during the period of the patch testing.

Discussion

The typical clinical picture of AGE is characterized by a rash with non-follicular sterile pustules on an edematous erythema accompanied

by fever above 38°C. In many cases, the skin lesions involve the face, intertriginous areas, trunk and lower limbs. Mucous membrane involvement may occur in about 20% of the patients but it is usually mild and remains limited to one site (oral surfaces). The average duration of the manifestations is 9.7 days, followed by a characteristic post-pustular desquamation [2]. Hematologic abnormalities include an increase of blood neutrophils, and sometimes, mild eosinophilia [14].

Histopathological analysis reveals subcorneal pustules with spongiosis. There is edema of the dermal papillae, perivascular infiltrate of neutrophils and eosinophils, and sometimes leukocytoclastic vasculitis, and necrotic keratinocytes [15]. Liver tests are usually normal. Hypocalcemia and mild elevation of aminotransferases can be observed [2].

Recently, Kavala et al. [11] reported the first case of AGE triggered by etanercept. A 29-year-old man with psoriasis developed erythroderma characterized by tiny pustules after the second etanercept injection. His pustules histopathologic examination revealed subcorneal and intraspinous collections of neutrophils with mild epidermal oedema (spongiosis) consistent with AGE. Bacterioscopy of the patient's blood and pustules were negative. His general health condition was good. In contrast, our patient developed systemic symptoms including fever, neutrophilia and elevation in the serum creatinine concentration. Additionally, she presented mild acute renal failure, which may occur in one-third of the patients with AGE [16].

Our patient presented most of the aspects, which characterize the syndrome, that is, lesion morphology, disease course and histological features, according to the EuroSCAR study group [14].

The differential diagnosis included pustular psoriasis and follicular eruptions. The presence of sterile pustules located mainly in intertriginous areas, together with the histopathologic features, were crucial for diagnostic certainty. Late-onset sepsis was probably related to *Klebsiella pneumoniae* nosocomial infection.

It's recognized that patients with AGE have revealed a high rate of positive patch tests when compared to patients with other types of cutaneous adverse reactions. In 2007, Seneschal et al. [6] reported patients who had experienced psoriasis form eruptions during anti-tumor necrosis factor therapy. The patients were patch tested with 30% etanercept and infliximab diluted in water or petroleum jelly. The diameters were measured after 48 hours and on the day 8. The authors reported a positive patch test showing edema and vesicles in one patient. For this reason, they considered that patch test for diagnosing anti-TNF-α adverse reactions would be adequate. It is speculated that proteases are secreted in the stratum corneum and would cleave anti-TNF-α in small fragments. Some authors [17] do not agree with the use of monoclonal antibodies for patch testing based on the concept that an allergen should have a **molecular weight less than 500 Da** in order to succeed in passing through the epidermis layer. This could partially explain the negativity of the patch test in our patient. On the other hand, at the time the patch test with etanercept was performed, she was being treated with adalimumab. According to Rosmarin et al. [18], TNF-α blockers would not contraindicate patch testing in patients under use of other anti-TNF agents. Other authors [6,7,19] also found negative results in patients with suspected adverse reaction to anti-TNF agents.

In conclusion, in daily medical practice, it is important to be alert to the possibility of serious skin reactions, such as AGE, in patients using

etanercept. A correct diagnosis of drug allergy is necessary in order that appropriate therapeutic interventions be employed.

Acknowledgement

This study was financially supported by the CNPq (process 554970/2010-4) and CAPES.

Conflicts of Interest

The authors declare no conflicts of interest.

References

1. Pastore S, Gubinelli E, Leoni L, Raskovic D, Korkina L (2008) Biological drugs targeting the immune response in the therapy of psoriasis. *Biologics* 2: 687-697.
2. Speeckaert MM, Speeckaert R, Lambert J, Brochez L (2010) Acute generalized exanthematous pustulosis: an overview of the clinical, immunological and diagnostic concepts. *Eur J Dermatol* 20: 425-433.
3. Halevy S (2009) Acute generalized exanthematous pustulosis. *Curr Opin Allergy Clin Immunol* 9: 322-328.
4. Moustou AE, Matekovits A, Dessinioti C, Antoniou C, Sfrikakis PP, et al. (2009) Cutaneous side effects of anti-tumor necrosis factor biologic therapy: a clinical review. *J Am Acad Dermatol* 61: 486-504.
5. Teixeira FM, Vasconcelos LM, Rola Cde A, Prata de Almeida TL, Valença JT Jr, et al. (2011) Secondary leprosy infection in a patient with psoriasis during treatment with infliximab. *J Clin Rheumatol* 17: 269-271.
6. Seneschal J, Lepreux S, Milpied B, Schaefferbeke T, Taïeb A (2007) Psoriasiform eruptions during anti TNF-alpha treatment: psoriasis or not? *Arch Dermatol* 143: 1593-1595.
7. Gonzalo-Garijo MA, Pérez-Calderón R, de Argila Fernández-Durán D (2008) Severe generalized exanthema due to etanercept given for severe plaque psoriasis. *Ann Allergy Asthma Immunol* 100: 621-622.
8. Williams VL, Cohen PR (2011) TNF alpha antagonist-induced lupus-like syndrome: report and review of the literature with implications for treatment with alternative TNF alpha antagonists. *Int J Dermatol* 50: 619-625.
9. McCain ME, Quinet RJ, Davis WE (2002) Etanercept and infliximab associated with cutaneous vasculitis. *Rheumatology (Oxford)* 41: 116-117.
10. Soliotis F, Glover M, Jawad AS (2002) Severe skin reaction after leflunomide and etanercept in a patient with rheumatoid arthritis. *Ann Rheum Dis* 61: 850-851.
11. Kavala M, Zindanci I, Turkoglu Z, Can B, Kocaturk E, et al. (2013) Acute generalized exanthematous pustulosis induced by etanercept: another dermatologic adverse effect. *Case Rep Dermatol Med* 2013: 601412.
12. Naranjo CA, Busto U, Sellers EM, Sandor P, Ruiz I, et al. (1981) A method for estimating the probability of adverse drug reactions. *Clin Pharmacol Ther* 30: 239-245.
13. Barbaud A (1995) Place of excipients in drug-related allergy. *Clin Rev Allergy Immunol* 13: 253-263.
14. Sidoroff A, Halevy S, Bavinck JN, Vaillant L, Roujeau JC (2001) Acute generalized exanthematous pustulosis (AGEP)--a clinical reaction pattern. *J Cutan Pathol* 28: 113-119.
15. Razera F, Olm GS, Bonamigo RR (2011) Neutrophilic dermatoses: part II. *An Bras Dermatol* 86: 195-209.
16. Leclair MA, Maynard B, St-Pierre C (2009) Acute generalized exanthematous pustulosis with severe organ dysfunction. *CMAJ* 181: 393-396.
17. Lecluse LL, Piskin G, Bos JD (2008) The use of patch tests in determining hypersensitivity to etanercept and infliximab. *Arch Dermatol* 144: 1070-1071.
18. Rosmarin D, Gottlieb AB, Asarch A, Scheinman PL (2009) Patch-testing while on systemic immunosuppressants. *Dermatitis* 20: 265-270.
19. Wee JS, White JM, McFadden JP, White IR (2010) Patch testing in patients treated with systemic immunosuppression and cytokine inhibitors. *Contact Dermatitis* 62: 165-169.