

Meningioma-Induced Transient Tumor Attacks Resembling Transient Ischemic Attacks

Hemasri T¹, Vishwaroop B² and Jagadeesh K Kalavakunta^{2*}

¹Department of Internal Medicine/Hematology-Oncology, Michigan State University, USA

²Department of Internal Medicine/Cardiology, Borgess Medical Center, USA

***Corresponding author:** Jagadeesh K Kalavakunta, Department of Internal Medicine/Hematology-Oncology, Michigan State University, East Lansing, 1521 Gull road, Kalamazoo, MI, USA, Tel: (269) 226-8374; Email: jkalavakunta@gmail.com

Case Report

Volume 1 Issue 4

Received Date: November 08, 2017

Published Date: December 15, 2017

DOI: 10.23880/mjccs-16000123

Abstract

Transient tumor attacks (TTA) are reversible neurological deficits similar to transient ischemic attacks (TIA) secondary to intracranial tumors especially supra tentorial tumors like meningiomas. A 55-year-old right-handed Caucasian woman was brought into emergency department with sudden onset of right lower extremity weakness. Neurological exam revealed a weakness of 2/5 in right lower extremity. Head computer tomography revealed a left frontal large extra axial mass consistent with meningioma. Her symptoms resolved in 2 hours. Vascular imaging and cardiac workup was within normal limits. She was started on high dose steroids and prophylactic antiepileptic medication. Surgical resection of the meningioma was performed with no recurrence of TIA.

Keywords: Transient tumor attacks; Meningiomas; Vascular insufficiency; Dyslipidemia; Antiepileptic

Abbreviation: TTA: Transient Tumor Attacks; TIA: Transient Ischemic Attacks; EEG: Electroencephalogram.

Case Presentation

A 55-year-old right handed Caucasian woman was brought to the emergency department with complaints of sudden onset of right lower extremity weakness. She did not have any significant past medical history specifically for hypertension, migraine, dyslipidemia or seizure disorder. On review of systems patient only complained of the right lower extremity weakness which was resolving from the time of onset. Vital signs were stable. Neurological exam revealed normal cranial nerve exam, normal fundoscopy, visual acuity and visual fields. Sensory exam showed normal pin prick, gross sensation

and temperature sensation bilaterally. Deep tendon reflexes revealed 2+ reflexes. Motor exam revealed normal tone, bulk and had 2/5 muscle strength in the right thigh flexors and leg extensors. Cerebellar exam for rapid alternating movements and finger tap were normal. In the next few hours her muscle weakness resolved and strength improved to 5/5.

Radiological investigation with a computer tomography scan of head revealed left frontal mass measuring 6.1 x 5.7 cm (Figure 1), with midline shift and the mass displacing the anterior falx nearly 2 cm from midline to the right with mass effect on both frontal horns. Radiologically the findings were consistent with a meningioma. Her electrocardiogram, echocardiogram, electroencephalogram (EEG), carotid ultrasound were

normal. Patient was started on steroids and prophylactic antiepileptic. On patient's request we transferred her to a tertiary care center. She had further evaluation with magnetic resonance angiography of the brain which did not reveal any vascular compromise. She underwent surgical resection of the meningioma with uneventful post-operative recovery. Since then she did not have any recurrence of TIAs on outpatient follow-up.

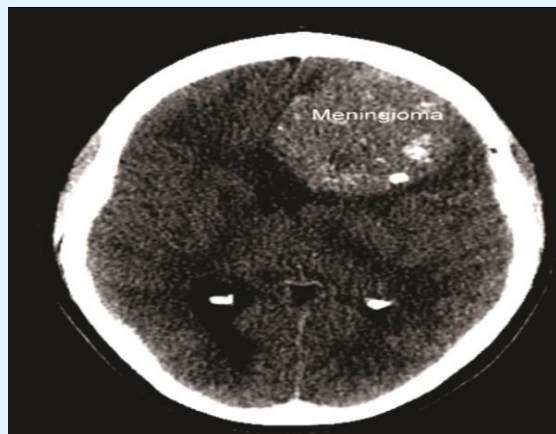


Figure 1: Computer tomography scan of head showing large left frontal meningioma with midline shift.

Discussion

Transient tumor attacks (TTA) are reversible neurological deficits similar to transient ischemic attacks (TIA) secondary to intracranial tumors. These symptoms usually occur with supra tentorial tumors especially meningiomas [1]. Due to their slow growth and the ability of the brain to accommodate the increase in intracranial pressure meningiomas are more likely to be associated with TTA. In two studies, around 8% of supratentorial meningiomas experienced intermittent and transient impairment of cerebral function [2,3].

In our case patient's presentation was similar to a TIA but an incidental brain tumor consistent with meningioma was found on head CT. The differential diagnosis included a transient tumor attack, seizure with a post ictal Todd's paralysis, TIA or mass effect from the tumor. Patient did not have any significant risk factors to have a TIA especially hypertension, dyslipidemia, diabetes, smoking or arrhythmia. TIA or stroke was less likely as MRI and MRA were within normal limits other than meningioma findings. The more difficult diagnostic dilemma is seizures with prominent negative symptoms [4]. An EEG was done which was negative for any epileptic form activity, therefore a lesser possibility of a seizure with Todd's paralysis. A seizure secondary to a

tumor is also a cause of transient tumor attack, but with a negative EEG during the weakness, seizure has a lesser likelihood. Gradual or stuttering onset of symptoms or association with symptoms related to increased intracerebral pressure can favour more towards TTA diagnosis [5]. Complete strokes related to meningioma are extremely rare as noted by a few case-reports in the literature.

A possible explanation for the transient neurological deficit in our patient is related to her intracranial tumor causing partial impairment of cerebral blood flow [6,7]. Her neurologic findings were more consistent with findings of vascular insufficiency related to her tumor causing compression of her left anterior cerebral artery or from mass effect by the tumor. When systemic blood pressure falls or tumor size increases critically, the cerebral blood flow decreases causing temporary cortical ischemia and paralysis of function. With a re-adjustment in cerebral blood flow, the cortical function returns. We did not perform a transcranial color-coded duplex sonography in this case but it will be prudent to do one as it can give us an insight into the vascular insufficiency related to the tumor compression or mass effect on the vasculature.

Several causes for decreased cerebral blood flow have been postulated such as 1) compression of the artery supplying the region, 2) steal phenomenon by the highly vascular tumors, 3) mass effect on the brain structures increasing the focal tissue pressure 4) regional increase in venous pressure due to the impediment of venous outflow [8].

In our case resolution of patient's transient neurological symptoms in a short period of time and head CT findings suggestive of meningioma along with no recurrence of TIA after resection of the meningioma are most consistent with a transient tumor attack.

Conclusions

Transient tumor attack should be included in the differential in patients with transient neurologic deficits with a radiologic finding of a brain tumor. Meningioma is the most common tumor associated with transient tumor attack. Treatment is resection of the tumor with complete resolution of symptoms with no recurrence.

Competing Interests

The authors declare that they have no competing interests.

References

1. Cameron EW (1994) Transient ischaemic attacks due to meningioma: Report of 4 cases. Clin Radiol 49(6): 416-418.
2. Daly DD, Svein HJ, Yoss RE (1961) Intermittent cerebral symptoms with meningiomas. Arch Neurol 5(3): 287-293.
3. Weisberg LA, Lacorte WS (1985) Computerized tomographic abnormalities in patients with transient episodes of focal neurological dysfunction. Comput Radiol 9(4): 247-254.
4. Garg A, Muniem A, Bhuyan S, Bansal AR (2014) Recurrent transient focal neurological deficits in convexity meningioma: TIA or negative motor seizures?. International Journal of Epilepsy 1(1): 39-42.
5. Nadarajan V, Perry RJ, Johnson J, Werring DJ (2014) Transient ischaemic attacks: mimics and chameleons. Pract Neurol 14(1): 23-31.
6. Komotar RJ, Keswani SC, Wityk RJ (2003) Meningioma presenting as stroke: report of two cases and estimation of incidence. J Neurol Neurosurg Psychiatry 74(1): 136-137.
7. Mathis S, Bataille B, Boucebci S, Jeantet M, Ciron J, et al. (2013) A rare cause of stroke in young adults: occlusion of the middle cerebral artery by a meningioma postpartum. Case Rep Neurol Med 2013: 652538.
8. Ueno Y, Tanaka A, Nakayama Y (1998) Transient Neurological Deficits Simulating Transient Ischemic Attacks in a Patient with Meningioma-Case Report. Neurol Med Chir 38(10): 661-665.

