

## Are There Any Problems with Siewert's Classification for Cancer of the Cardia ?

Toshihiro HIRAI, Hideo MATSUMOTO, Yoko HIRABAYASHI,  
Masaharu IKEDA, Masahiro YAMAMURA, Tadahiko KUBOZOE,  
Katsumichi IKI, Atsushi URAKAMI, Kazuki YAMASHITA  
and Tsukasa TSUNODA

*Department of Gastroenterological Surgery, Kawasaki Medical School,  
Kurashiki 701-0192, Japan*

*Accepted for publication on July 2, 2004*

**ABSTRACT.** The optimal surgical approach for adenocarcinoma of the gastroesophageal junction has been controversial, even with the appearance of an anastomotic instrument. Recently, Siewert's classification of adenocarcinoma of the gastroesophageal junction has come into popular use for deciding on the operative procedure for carcinoma of the cardia. However, there are some unresolved problems regarding its practical use is not authorized with regard to the safety resection margin of the esophagus. The classification is made from the location of the tumor center and its concepts are based on the trend of the lymphatic spread of Type I, II and III tumors. However, the area of the lymph nodes which can be dissected in transhiatal blunt dissection and an extended total gastrectomy under division of the central tendon of the diaphragm does not differ. Selection of operative procedure should be based on the clearance from the neoplasm at the resection margin, if the tumor was resected curatively. Our indications for operative procedures for carcinoma of the cardia seem to be more legitimate than Siewert's classification because the decision is based on a precise analysis of skip lesions and residual tumors on the remaining esophagus. We would like to emphasize that a decision regarding the resection line and operative procedure should be made before an operation, because it could be quite difficult to do so during the operation since ; (1) a skip lesion usually cannot be detected, (2) frozen section examination is unreliable for determining tumor clearance of the resection margin, and (3) the surgeon might wish to avoid changing the operative procedure to a more stressful one.

**Key words :** carcinoma — gastroesophageal junction —  
Siewert's classification — skip lesion

The optimal surgical approach for adenocarcinoma of the gastroesophageal junction has been controversial, even with the appearance of an anastomotic instrument. Some authors have advocated the use of a left thoracotomy and laparotomy, while others have recommended a laparotomy only. After Siewert and Stein published a paper entitled "Carcinoma of the cardia: Carcinoma of the gastroesophageal junction-

classification, pathology and extent of resection” in 1996, many surgeons chose to use this classification because its clinical use is very simple and easy. However, Siewert’s classification includes some unfesolved practical problems. In this paper, these problems will be discussed, and more practical indications, which we would like to emphasize, are proposed.

### Siewert’s classification for carcinoma of the cardia

Siewert and Stein advocated a classification for carcinoma of the gastroesophageal junction.<sup>1)</sup> They had already defined and described carcinomas of the gastroesophageal junction as tumors that have their center within 5 cm orally or aborally of the anatomical gastroesophageal junction.<sup>2)</sup> From therapeutic and prognostic points of view, three distinct tumor entities were proposed, as shown in Fig 1. If the tumor center or more than two

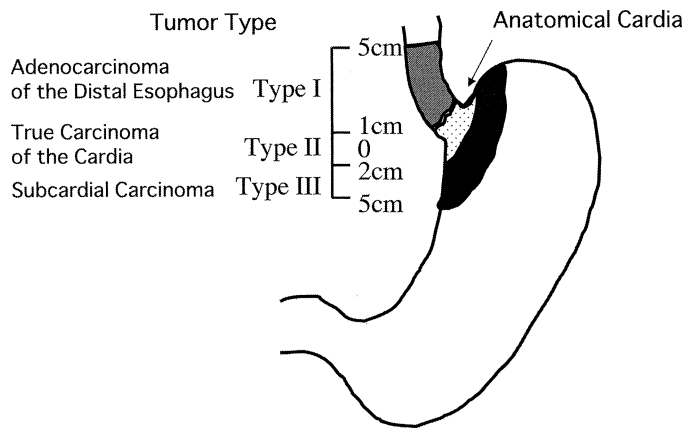


Fig 1. Siewert’s classification of adenocarcinoma of the gastroesophageal junction based on the location of the tumor center or more than two third of the tumor mass.

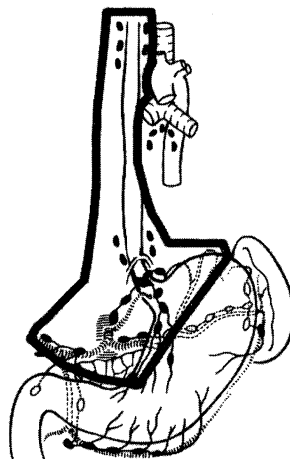


Fig 2. Recommended extent of resection for patients with adenocarcinoma of the distal esophagus (Type I) by Siewert; Radical transhiatal esophagectomy + 2-field lymph node dissection.

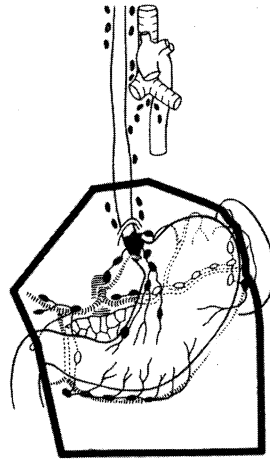


Fig 3. Recommended extent of resection for patients with true carcinoma of the cardia and subcardial adenocarcinoma (Type II and III) by Siewert; Extended total gastrectomy with D2 lymph node dissection (pancreas preserving splenectomy).

thirds of the tumor mass is located more than 1 cm above the anatomical gastroesophageal junction, the tumor is classified as an adenocarcinoma of the distal esophagus (Type I). If the tumor center or tumor mass is located within 1 cm orally or 2 cm aborally of the anatomical gastroesophageal junction, the tumor is classified as a true carcinoma of the cardia (Type II). Adenocarcinomas of the gastroesophageal junction that have their tumor center or more than two thirds of the tumor mass located more than 2 cm below the anatomical gastroesophageal junction are classified as subcardial tumors (Type III). For a Type I tumor, a radical transhiatal esophagectomy plus 2-field lymph node dissection (Fig 2) should be adopted. For Type II and III tumors, an extended total gastrectomy with D2 lymph node dissection should be adopted (Fig 3). This classification immediately becomes popular on without delay because it wes really simple and easy to use.

#### **Our clinico-pathological analysis and choice of surgical procedure for gastric cancer involving the esophagus**

We are adopted three types operative procedures for gastric cancer involving the esophagus. They are transabdominal resection and cervical anastomosis obviating thoracotomy, esophagojejunostomy with the anastomotic instrument in the mediastinum (extended total gastrectomy) and transhiatal esophagectomy, as previously reported in detail.<sup>3)</sup> One hundred resected specimens which showed obvious histological tumor invasion of the esophagus in a precise histological examination using stepwise 5 mm thick sections were investigated and analyzed clinico-pathologically with special reference to skip lesions in the esophagus. We had an interest in the skip lesions because we noticed that some cases had a skip lesion in the esophagus quite distal from the primary tumor. In this study, the gastroesophageal junction was considered to be the cardiac orifice macroscopically. The abbreviations OW and ow are used for the distances

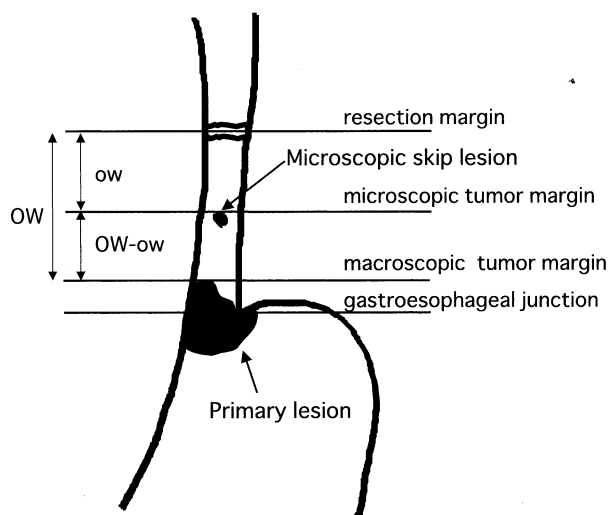


Fig 4. Diagrammatic representation of OW-ow.

measured from the tumor to the resected esophageal margin macroscopically (OW) and microscopically (ow), respectively. (OW-ow) signifies the difference between the macroscopic tumor margin and the microscopic one (Fig 4).

Our results showed that 24 cases had skip lesions apart from the main lesion in the esophagus. As for histological type, the incidence of poorly differentiated adenocarcinomas (por) was highest in the skip lesions (Table 1). The average (OW-ow)s were subdivided according to histological types (Table 2). The group with por or signet-ring cell type (sig) tumors among skip cases had significantly larger figures for (OW-ow) than those of non-skip cases. The maximum length of the (OW-ow) was 89 mm. From our experience, the average length of the resected esophageal portion in

TABLE 1. Our analysis of histological types and skip lesions

Histological type	Number of skip cases	Number of non-skip cases	Total
pap	1 ( 4)	9 ( 12)	10 ( 10)
tub 1	0	15 ( 20)	15 ( 15)
tub 2	6 ( 25)	24 ( 32)	30 ( 30)
por	10 ( 42)	21 ( 28)	31 ( 31)
sig	2 ( 8)	5 ( 7)	7 ( 7)
muc	4 ( 17)	2 ( 3)	6 ( 6)
cd	1 ( 4)	0	1 ( 1)
Total	24 (100)	76 (102)	100 (100)

Pap: papillary adenocarcinoma, tub: tubular adenocarcinoma, well differentiated type, tub 2: tubular adenocarcinoma, moderately differentiated type, por: poorly differentiated adenocarcinoma, sig: signet-ring cell carcinoma, muc: mucinous adenocarcinoma, cd: carcinoid tumor  
( ): %

TABLE 2. Our analysis of histological types and average length of the (OW-ow) distance (mm)

Histological types	Skip cases (N)	Non-skip cases (N)	Total (N)
pap	-8 ( 1)	6.6± 8.0 ( 9)	6.5± 6.8 (10)
tub 1	( 0)	4.0±13.3 (15)	4.0±13.3 (15)
tub 2	5.7±17.2 ( 6)	0.3±14.4 (24)	5.8± 9.1 (30)
por*	29.2±24.2 (10)	0.6±23.0 (21)	12.0±23.3 (31)
sig*	47.0± 1.4 ( 2)	21.2±16.0 ( 5)	28.6±16.8 ( 7)
muc	3.8±19.3 ( 4)	13.5±16.3 ( 2)	7.8±15.0 ( 6)
cd	6 ( 1)		6 ( 1)
Total	18.0±24.0 mm (24)	3.6±17.1 mm (76)	7.0±19.9 mm(100)

\* : p<0.05 ; significant difference in skip and non-skip cases

TABLE 3. Our analysis of the maximum length of the (OW-ow) distance (mm)

histological type	the length of macroscopic esophageal invasion (mm)				
	>0, ≤10,	>10, ≤20,	>20, ≤30,	>30, ≤40	>40
differentiated	30	24	24	25	16
type*1	(50)*3	(54)	(64)	(75)	(>66)
undifferentiated	47	89	48	23	10
type*2	(67)	(109)	(88)	(73)	(>60)

\*1 : Differentiated type means papillary and tubular adenocarcinoma.

\*2 : Undifferentiated type means poorly differentiated and signet-ring cell adenocarcinoma.

\*3 : ( ) ; safe resection margin of the esophagus from the gastroesophageal junction, the length of which was calculated by the formula ; maximum length of macroscopic esophageal invasion in each group + maximum length of the (OW-ow) in each group + 10 mm.

extended gastrectomy has been  $40.5 \pm 13.1$  mm.<sup>3)</sup> If an extended gastrectomy were indicated for all cases, some cases might have residual tumor tissue in the esophagus. However, it is unusual to adopt transhiatal esophagectomy for all cases. To decide on a safe resection margin for the esophagus, we divided the cases on the basis of the length of macroscopic esophageal invasion and classified them according to their histological types. The (OW-ow) distance of each case was measured and the maximum (OW-ow) distance was determined in each group. The safe resection margin of the esophagus from the gastroesophageal junction was decided on based on the following principle: the maximum distance of macroscopic esophageal invasion in each group + the maximum distance of the (OW-ow) in each group + 10 mm. For instance, in the group with macroscopic esophageal invasion from 0 to 10 mm, the maximum length of the (OW-ow) distance was 30 mm. Therefore; the safe resection margin of the esophagus from the gastroesophageal junction in this group was 10 mm (maximum length of macroscopic esophageal invasion) + 30 mm (maximum length of (OW-ow) distance in this group) + 10 mm, that is, 50 mm. This calculation was performed for all of the groups. The results are summarized in Table 3, and the safe resection margin of the gastroesophageal junction for each

group is shown in parentheses in that table. In an extended total gastrectomy, the length of the resected esophagus is approximately 50 mm. Based on these results, an extended gastrectomy could be indicated for a well-differentiated adenocarcinoma with macroscopic esophageal invasion of less than 20 mm. A transhiatal esophagectomy should basically be indicated for cases of well-differentiated adenocarcinoma with macroscopic esophageal invasion of more than 21 mm and all cases of poorly differentiated adenocarcinoma. However, as we have previously reported, based on our clinical outcomes, an extended gastrectomy could be indicated for cases of undifferentiated adenocarcinoma with minimal invasion of less than 10 mm and for palliative cases.<sup>4)</sup>

### DISCUSSION

The optimal surgical procedure for carcinoma of the cardia has been discussed and even now is controversial. The most important point at issue is the resection margin, which is directly related to the surgical approach; with or without thoracotomy, or a subtotal esophagectomy using a transhiatal blunt esophagectomy approach or a gastrectomy plus resection of the lower part of the esophagus (an extended total gastrectomy). The resection margin has been discussed here because recurrence at the resection margin has been reported to reduce the survival rate.<sup>5,6)</sup>

Siewert's classification is not authorized with regard to the safety resection margin of the esophagus. Classification is made from the location of the tumor center, but even when the tumor center is located within 1 cm orally and 2 cm aborally of the anatomical gastroesophageal junction (Type II), a huge or invasive tumor can be far from the gastroesophageal junction. Basically, it is unreasonable to select an operative procedure or approach from the view point of the tumor center.

The concepts of Siewert's classification were based on the trend of the lymphatic spread of Type I, II and III tumors. However, the area of the lymph nodes which can be dissected in a transhiatal blunt dissection and an extended total gastrectomy under division of the central tendon of the diaphragm does not differ. In addition, we have had no case of lower mediastinal lymph node recurrence as a first recurrence site. Therefore, the operative procedure should be selected based on the clearance from the neoplasm at the resection margin, if the tumor was resected curatively.

Siewert *et al* noted that a clear oral resection margin should be confirmed intraoperatively by frozen sections in patients with "diffuse-type tumors". However, Papachristou *et al*<sup>6)</sup> reported that while frozen section examination of the esophageal margin before construction of the anastomosis was carried out in 130 patients, of those 10 subsequently developed recurrence at the anastomosis despite the fact that their margins were clear histologically. This could be explained by the existence of skip submucosal lesions which have been reported by Papachristou *et al*<sup>6)</sup>, Morson<sup>7)</sup> and authors.<sup>3)</sup> The resection line and operative procedure should be decided before an operation. Otherwise, it could be quite difficult to do during the operation since; (1) a skip lesion usually cannot be detected, (2) frozen section examination is unreliable for determining tumor clearance of the

resection margin, and (3) the surgeon might wish to avoid changing the operative procedure to a more stressful one.

For these reasons, our indications for operative procedures for carcinoma of the cardia seem to be more legitimate than Siewert's classification, although it has become quite popular. In both Siewert's classification and, of course, our indications, there is a serious problem to be resolved. That is the difficulty in deciding on the esophagogastric junction line preoperatively. Siewert *et al*<sup>1)</sup> stated that a two-plane radiograph with barium contrast of the entire esophagus and proximal stomach provides the best information for the categorization of these tumors. However, in their initial paper, they did not state how the EG junction was to be decided upon. In the first place, what is the EG-junction? Is it the mucosal junction, vascular junction, luminal junction, or muscular junction? Our data were analyzed on the basis of the luminal junction of the resected specimen. However, it is difficult to make such an analysis when EG-junction has been destroyed by cancer invasion. Therefore, the method for deciding on the EG-junction should be stated when carcinoma of the cardia is discussed.

From our experience, in palliatively resected cases, residual tumors at the resection line do not influence either the prognosis or the quality of life. However, a significant increase in true cardia early cancers has been reported in Japan.<sup>8)</sup> Patients with early stage cardiac carcinoma live longer and have a greater chance of developing recurrence at the anastomosis.<sup>9)</sup> Although, Siewert's classification for cancer of the cardia was approved at a consensus conference during the Second International Gastric Cancer Congress<sup>9)</sup> held in 1997, attention now should be focused on skip lesions and the safe resection line of the esophagus should be discussed again.

#### REFERENCES

- 1) Siewert JR, Stein HJ: Carcinoma of the cardia: Carcinoma of the gastroesophageal junction-classification, pathology and extent of resection. *Dis Esophagus* **9**: 173-182, 1996
- 2) Siewert JR, Holscher AH, Becker K, Grossner W: Kardiakarzinom. Versuch einer therapeutisch relevanten Klassifikation. *Chirurg* **58**: 25-34, 1987
- 3) Hirai T, Yamamoto A, Yamashita Y, Mukaida H, Iwata T, Saeki S, Toge T: Clinico-pathological analysis of skip lesions of gastric cancer involving the oesophagus. *Asian J Surgery* **16**: 44-52, 1993
- 4) Hirai T, Yamashita Y, Iwata T, Yoshimoto A, Noma K, Kuwahara M, Toge T: Clinicopathologic findings in gastric cancer involving the esophagus and indications for transhiatal esophagectomy. *Jpn J Cancer Clin* **42**: 1092-1098, 1996
- 5) Alfonso A, Rosen P, Guerra O, Fortner J: Adenocarcinoma of the proximal third of the stomach-pitfalls in surgical management. *Am J Surg* **134**: 326-330, 1977
- 6) Papanchristou DN, Fortner JG: Anastomotic failure complicating total gastrectomy and esophagectomy for cancer of the stomach. *Am J Surg* **138**: 399-402, 1979
- 7) Morson BC: The spread of carcinoma of the esophagus. In: Tanner NC and Smithers DW(ed.) *Tumors of the esophagus*. Edinburgh, Livingstone, pp136-146, 1961
- 8) Blaser MJ, Saito D: Trends in reported adenocarcinomas of the oesophagus and gastric cardia in Japan. *Eur J Gastroenterol Hepatol* **14**: 107-113, 2002
- 9) Kodera Y, Yamamura Y, Shimizu Y, Torii A, Hirai T, Yasui K, Morimoto T, Kato T: Adenocarcinoma of the gastroesophageal junction in Japan: relevance of Siewert's classification applied to 177 cases resected at a single institution. *J Am Coll Surg* **189**: 594-601, 1999