

## Age Estimation Using S-100 Protein-Positive Stellate Cells in Anterior Pituitary

Takaki ISHIKAWA, Toshiaki TACHIBANA\*, Satoru MIYAISHI  
and Hideo ISHIZU

*Department of Legal Medicine,  
Graduate School of Medicine and Dentistry, Okayama University,  
Okayama, Japan*

*\*Department of Anatomy, Jikei University School of Medicine,  
Tokyo, Japan*

*Accepted for publication on September 10, 2003*

**ABSTRACT.** We examined the embryonic development as well as postnatal development of S-100 protein-positive stellate cells in the anterior lobe of human hypophysis using immunohistochemical method, and investigated the possibility of using the frequency of the stellate cells for age estimation. A definite positive correlation was observed between the proportion of the stellate cell and age, in both males ( $r=0.987$ ) and females ( $r=0.986$ ). The linear regression equation was  $y=0.206x-1.82$  for males and  $y=0.239x-2.22$  for females ( $x$ : age,  $y$ : percentage of S-100 protein-positive stellate cells). Although the reason for an increase in stellate cells with age remains unknown, the present results indicate that the proportion of stellate cells in the anterior pituitary can be applied reliably to estimate age.

**Key words:** pituitary — S-100 protein — age estimation

Using immunohistochemical methods, Nakajima<sup>1)</sup> and Cocchia & Miani<sup>2)</sup> demonstrated the presence of S-100 protein in the folliculo-stellate cells of rat adenohypophysis and the cells bordering the pars intermedia and adenohypophysis in contact with the vestigial Rathke pouch. Furthermore, the postnatal development of these cells in rats was described by Shirasawa.<sup>3)</sup> However, our search of literature found no report on the postnatal development of S-100 protein-positive stellate cells and how they change with age, or whether these cells may be used to estimate age. In the present study, we used immunohistochemical method to investigate the embryonic genesis and postnatal development of stellate cells in humans hypophysis and the possibility of using the proportion of the stellate cells in age estimation.

### MATERIALS AND METHODS

The hypophysis specimens from 3 human dead fetuses (gestation age: 10 to 36 weeks) and 132 corpses (age: 0 to 100 years) with no endocrinological diseases, alcohol-related diseases, liver diseases, psychological diseases, or malignant tumors were studied. After excision at

---

石川隆紀, 立花利公, 宮石 智, 石津日出雄,  
e-mail: takaki@med.kawasaki-m.ac.jp

autopsy, the hypophysis specimens were fixed by shaking in 10% formalin for 3 days at 4°C. Then, the dura was removed under a stereomicroscope. After embedding in paraffin, 4- $\mu$ m serial frontal sections\* were prepared in three regions, the anterior, central, and posterior third of the hypophysis. The serial sections in each region were immunostained by the ABC method using rabbit anti-bovine S-100 polyclonal antibodies (Polyclonal, whole (both  $\alpha$  and  $\beta$  subunits), 1:5000 diluted, supplied by the Department of Anatomy, Jikei University, School of Medicine, Tokyo, Japan),<sup>4)</sup> and visualised by 3,3'-diaminobenzidine (DAB). The proportion of the area occupied by S-100 protein-positive stellate cells to the whole area of the anterior pituitary section was measured using an Olympus Color Image Analyzer (CIA102, Olympus, Tokyo, Japan). The correlation between the proportion of stellate cells in the anterior pituitary and age was analysed by linear regression method. Since the S-100 protein containing cells present in the pars intermedia was a cause of variation in age estimation, only the S-100 protein-positive stellate cells in the anterior pituitary was examined in the present study.

## RESULTS

In the hypophysis sample of the 34-gestational-week fetus, S-100 protein containing stellate cells were observed at the border of the posterior lobe and the pars intermedia, on surfaces facing the lumen of follicles in the pars intermedia, and sites in contact with the vestigial Rathke pouch (Fig 1). At the age of 7 years, a small number of the stellate cells appeared in the ventrolateral region of the anterior pituitary. In the anterior pituitary at 13 years of age, the number of stellate cells increased in the ventrolateral region, and stellate cells began to appear also in the adenohipophyseal region in contact with the pars intermedia. From 20 years of age, the number of stellate cells gradually increased mainly in the ventrolateral region

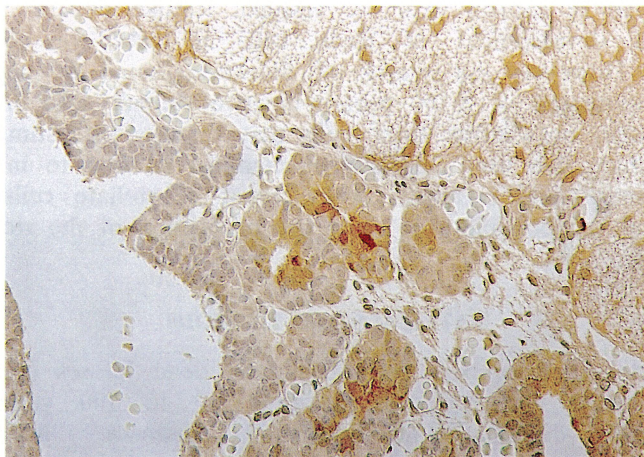


Fig 1. Immunostaining of S-100 protein-containing cells in the hypophysis of human fetus at 34 gestational week. S-100 protein containing cells are seen on the surface facing the lumen of pars intermedia follicles (Magnification  $\times 200$ ).

of the anterior pituitary and the region in contact with the pars intermedia follicles, and progressively spread to the whole region of the anterior pituitary (Fig 2). The stellate cells were distributed almost in the whole of the anterior pituitary in the forties, and completely covered the whole region in the sixties. In the eighties, stellate cells occupied approximately 20% of the whole area of the anterior pituitary section (Fig 3). Stellate cells were more abundant in females than in males throughout life. A definite positive correlation was observed between the proportion of stellate cells in the anterior pituitary and age in both males ( $r=0.987$ ) and females ( $r=0.986$ ). The linear regression equation was  $y=0.206x-1.82$  for males (Fig 4) and  $y=0.239x-2.22$  for females (Fig 5) ( $x$ : age,  $y$ : percentage of the area occupied by S-100 protein-positive stellate cells).

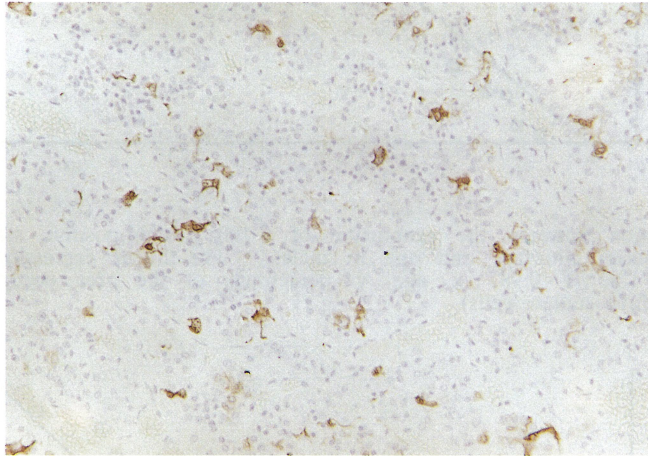


Fig 2. Immunostaining of S-100 protein-positive stellate cells in the hypophysis of a human subject aged 20 years. (Magnification  $\times 200$ ).

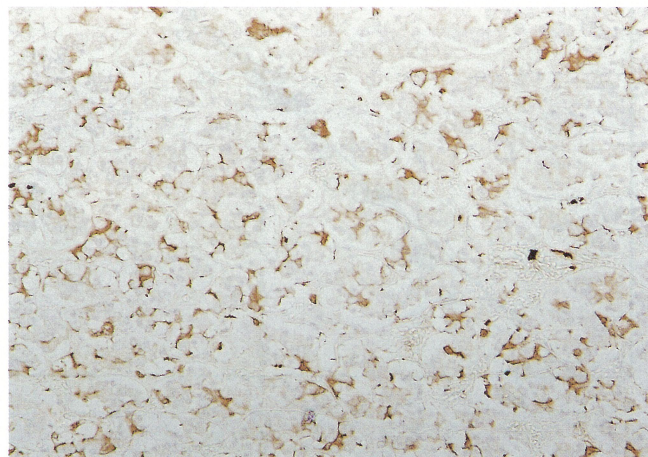


Fig 3. Immunostaining of S-100 protein-positive stellate cells in the hypophysis of a human subject aged 80 years. In the eighties, S-100 cells occupy approximately 20% of the whole area of the anterior pituitary section (Magnification  $\times 200$ ).

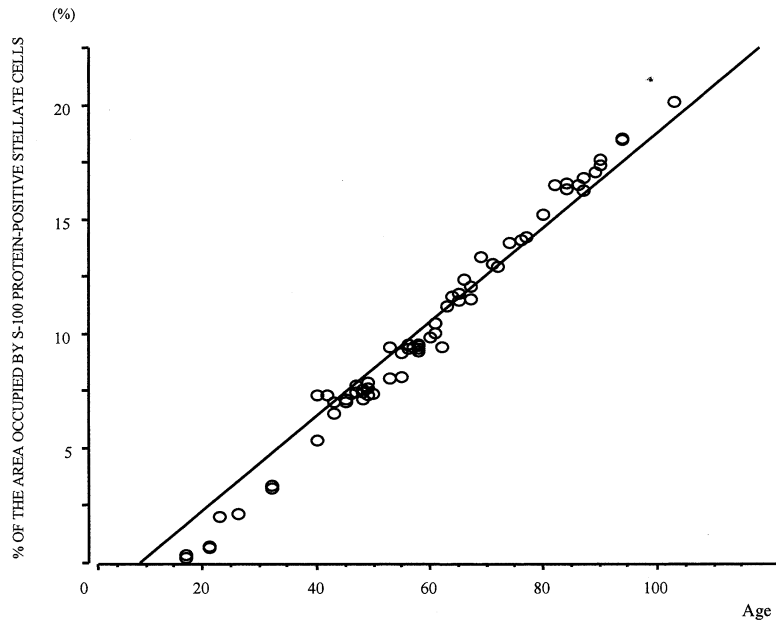


Fig 4. Correlation between the proportion of S-100 protein-positive stellate cells in human anterior pituitary and age in males. The linear regression equation is  $y=0.206x-1.82$  ( $r=0.987$ ;  $x$ : age,  $y$ : percentage of the area occupied by S-100 protein-positive stellate cells).

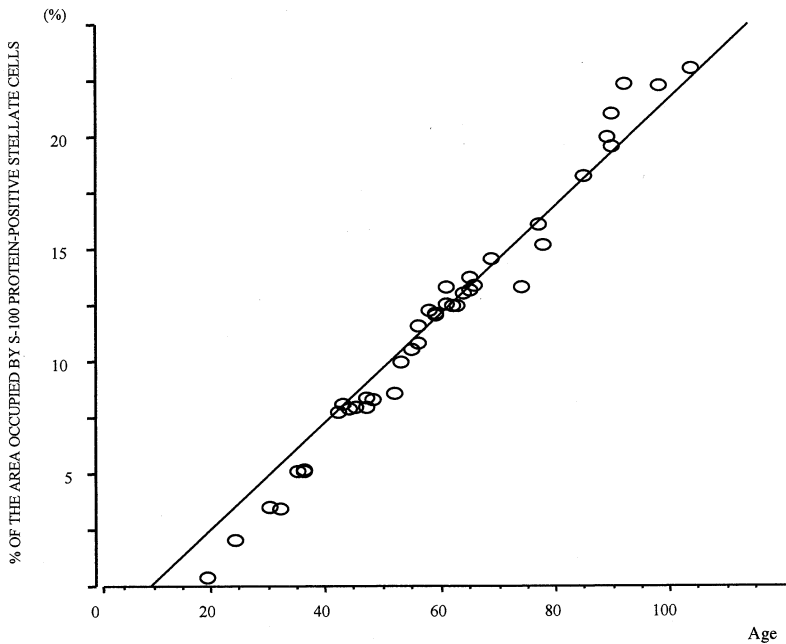


Fig 5. The correlation between the proportion of S-100 protein-positive stellate cells in human anterior pituitary and age in females. The linear regression equation is  $y=0.239x-2.22$  ( $r=0.986$ ;  $x$ : age,  $y$ : percentage of the area occupied by S-100-positive cells).

## DISCUSSION

S-100 protein was first isolated by Moore<sup>5)</sup> and Moore & McGregor<sup>6)</sup> as a soluble protein specific to the nervous system, and was found to be a calcium-binding protein.<sup>7)</sup> Further studies have demonstrated that the S-100 protein is distributed in astroglial cells, oligodendroglial cells and ventricular ependymal cells of the central nervous system; and is present specifically in neurilemma cells and mantle cells of the peripheral nervous system.<sup>8)</sup> Recently, S-100 protein-positive cells have been identified in tissues outside the nervous system. Melanocytes in the skin,<sup>9)</sup> Langerhans cells,<sup>10,11)</sup> interdigitating reticulum cells of the lymph node,<sup>10,12)</sup> myoepithelial cells,<sup>13)</sup> adipocytes,<sup>14)</sup> and chondrocytes<sup>15)</sup> are now known to contain S-100 protein.

The localisation of S-100 protein in the hypophysis was reported by Nakajima *et al*<sup>1)</sup> and Cocchia & Miani,<sup>2)</sup> who demonstrated by immunohistochemical methods that the folliculo-stellate cells of rat adenohypophysis and the bordering cells between the pars intermedia and adenohypophysis in contact with the vestigial Rathke pouch contained S-100 protein. Thereafter, Shirasawa *et al*<sup>3)</sup> reported the postnatal development of S-100-containing cells in rats hypophysis. However, as far as we are aware, there is no report on the postnatal development of S-100 protein-positive stellate cells, or whether these cells may be used in age estimation. In the present study, we used immunohistochemical methods to investigate the postnatal development of stellate cells and the possibility of using the occurrence of stellate cells in age estimation.

The S-100 protein exists as a dimer composed of combinations of two subunits, S100 $\alpha$  and S100 $\beta$ . Three isozymes; S100a( $\alpha\alpha$ ), S100a( $\alpha\beta$ ) and S100b( $\beta\beta$ ) have been identified.<sup>16)</sup> In the present study, rabbit anti-bovine S-100 polyclonal antibodies (supplied by Jikei University School of Medicine) were used, which react with both S100 $\alpha$  and S100 $\beta$ .<sup>4)</sup> The results of this study showed an increase in the number of S-100 protein-positive stellate cells in the anterior pituitary with increasing age, and these cells occupied approximately 20% of all secretory cells in the anterior pituitary of subjects in the eighties. Statistical analysis showed a definite correlation between the proportion of stellate cells and age.

Although many immunohistochemical studies have been conducted to examine the histologic localisation of S-100, there is no consensus yet regarding the biological significance of this protein. Tabuchi *et al*,<sup>17)</sup> Pfeiffer *et al*<sup>18)</sup> and Labourdette *et al*<sup>19)</sup> showed that the S-100 protein was associated with cell differentiation in cultured glioma cells. On the other hand, a wide range of functions have also been reported by other authors, such as synapse regulation,<sup>20)</sup> involvement in intranuclear function,<sup>21)</sup> activation of protein kinase,<sup>22)</sup> involvement in microvascular disassembly,<sup>23)</sup> and involvement in hormone secretion.<sup>24)</sup> In their later study, Nakajima *et al*<sup>25)</sup> showed that the S-100 protein was present in the extracellular and cerebrospinal fluids at concentrations several hundred-fold higher than the intracellular concentration. They speculated the presence of a mechanism of extracellular release of the S-100 protein as well as the possible involvement of the S-100 protein in cation transport between cells. In any case, the definitive role of the S-100 protein has yet to be decided. In the present

study, the reason for an increase in stellate cells with aging remains unknown. However, the present results indicate a definite positive correlation between the stellate cells in the anterior pituitary and age, and we consider that this parameter can be applied to estimate age.

#### ACKNOWLEDGMENTS

We express our sincere gratitude to Professor Demon C Herbert (Professor of Department of Cellular and Structural Biology, The University of Texas, Health Science Center at San Antonio, Texas) for critically reviewing this manuscript.

#### REFERENCES

- 1) Nakajima T, Yamaguchi H, Takahashi K: S-100 protein in folliculostellate cells of the rat pituitary anterior lobe. *Brain Res* **191**: 522-531, 1980
- 2) Cocchia D, Miani N: Immunocytochemical localization of the brain-specific S-100 protein in the pituitary gland of adult rat. *J Neurocytol* **9**: 771-782, 2001
- 3) Shirasawa N: Immunohistochemical studies of S-100 protein and folliculo-stellate cells in various mammals (in Japanese). *Acta Anatomica Nipponica* **58**: 347, 1983
- 4) Shirasawa N, Yamaguchi S and Yoshimura F: Granulated folliculo-stellate cells and growth hormone cells immunostained with anti-S100 protein serum in the goat pituitary glands. *Cell Tissue Res* **237**: 7-14, 1984
- 5) Moore BW: A soluble protein characteristic of the nervous system. *Biochem Biophys Res Commun* **19**: 739-744, 1965
- 6) Moore BW, McGregor: Chromatographic and electrophoretic fractionation of soluble proteins of brain and liver. *J Biol Chem* **240**: 1647, 1965
- 7) Weiss AC, Dorfman HD: S-100 protein in human cartilage lesions. *J Bone Joint Surg* **68**: 521-526, 1986
- 8) Nakajima T, Ishihara K: S-100 protein (in Japanese). *Hifu Rinsho* **26**: 1081-1088, 1986
- 9) Nakajima T, Watanabe S, Sato Y, Kameya T, Shimosato Y, Ishihara K: Immunohistochemical demonstration of S-100 protein in malignant melanoma and pigmented nevus, and its diagnostic application. *Cancer* **50**: 912-918, 1982
- 10) Nakajima T, Watanabe S, Sato Y, Shimosato Y, Motoi M, Lennert K: S-100 protein in Langerhans cells, interdigitating reticulum cells and histiocytosis X cells. *Gann* **73**: 429-432, 1982
- 11) Heshmatl HM, Kujas M, Turpin G, Gremain J, Jacque CM, Racadot J: Immunohistochemical localization of protein S-100 in the normal human pituitary gland. *Press Med* **29**: 621-622, 1986
- 12) Takahashi K, Yamaguchi H, Ishizeki J, Nakajima T, Nakazato Y: Immunohistochemical and immunoelectron microscopic localization of S-100 protein in the interdigitating reticulum cells of the human lymph node. *Virchows Arch B Cell Patho Incl Mol Pathol* **37**: 125-135, 1981
- 13) Nakajima T: Immunohistochemical studies of tumors associated with nerve tissue-specific proteins (S-100 and NSE proteins), and application to diagnosis (in Japanese). *Byori To Rinsho* **1**: 115-123, 1983
- 14) Michetti F, Dell'Anna E, Tiberio G, Cocchia D: Immunochemical and immunocytochemical study of S-100 protein in rat adipocytes. *Brain Res* **262**: 352-356, 1983
- 15) Steffansson K, Wollmann RL, Moore BW, Arnasson BGW: S-100 protein in human chondrocytes. *Nature* **295**: 63-64, 1982
- 16) Isobe T, Ishioka N, Okuyama N: Cerebral proteins, Calmodulin and S-100 protein (in Japanese). *Shinkei Shinpo* **24**: 983-1007, 1980
- 17) Tabuchi K, Furuta T, Norikane H, Tsuboi M, Moriya Y, Nishimoto A: Evaluation of the drug-induced morphological differentiation of rat glioma cells (C-6) from the aspects of S-100 protein level and con A binding pattern. *J Neurol Sci* **51**: 119-130, 1981
- 18) Pfeiffer SE, Herschman HR, Lightbody J, Sato G: Synthesis by a clonal line of rat

- glial cells of a protein unique to the nervous system. *J Cell Physiol* **75**: 329-340, 1970
- 19) Labourdette G, Marks A: Synthesis of S-100 protein in monolayer cultures of rat-glial cells. *Eur J Biochem* **58**: 73-79, 1975
  - 20) Hyden H: A calcium-dependent mechanism for synapse and nerve cell membrane modulation. *Proc Natl Acad Sci USA* **71**: 2965-2968, 1974
  - 21) Marks A, Labourdette G: Succinyl concanavalin A stimulates and antimicrotubular drugs inhibit the synthesis of a brain-specific protein in rat glial cells. *Proc Natl Acad Sci USA* **74**: 3855-3858, 1977
  - 22) Qi DF, Turner RS, Kuo JF: S-100 and other acidic proteins promote  $Ca^{2+}$ -independent phosphorylation of protamine catalyzed by a new protein kinase from brain. *J Neurochem* **42**: 458-465, 1984
  - 23) Baudier J, Briving C, Deinum J, Haglid K, Sorskog L, Wallin M: Effect of S-100 proteins and Calmodulin on  $Ca^{2+}$ -induced disassembly of brain microtubule proteins in vitro. *FEBS Lett* **147**: 165-168, 1982
  - 24) Shashoua VE, Hesse GW, Moore BW: Proteins of the brain extracellular fluid: Evidence for release of S-100 protein. *J Neurochem* **42**: 1536-1541, 1984
  - 25) Nakajima T, Sato Y, Watanabe S, Shimosato Y, Ishihara K, Isobe T: Immunoelectron microscopical demonstration of S-100 protein in epidermal Langerhans cells. *Biomed Res* **3**: 226-231, 1982