

CASE REPORT / OLGU BİLDİRİSİ

A case with Herpes Zoster Oticus involving multiple cranial nerves

A. Yenigün, M. F. Evcimik, H.D. Tansuker, Ö. F. Çalım

Multipl kranial sinir tutulumu gösteren Herpes Zoster Oticus olgusu

Herpes Zoster Oticus; virüs kaynaklı bir genikulat ganglion inflamasyonu kulak kepçesinde herpetik döküntü ile ilişkili fasiyal paralizi olarak tanımlanmıştır. Bununla birlikte bu durum sadece bir genikulat ganglion inflamasyonunu değil polikranial bir nöriti temsil eder. Burada multipl kranial sinir tutulumu ile birlikte herpes zoster otikus olgusu literatür eşliğinde tartışıldı.

Anahtar Sözcükler: Herpes Zoster Oticus, genikulat ganglion, polikranial nörit.

Türk Otolarengoloji Arşivi, 2012; 50(3):54-56

Abstract

Herpes Zoster Oticus described a virus caused by facial nerve paralysis associated with herpetic eruption of the pinna and suggested that it resulted from a geniculate ganglionitis. However, this condition represents a polycranial neuronitis and not simply a geniculate ganglionitis. We here present a Herpes Zoster Oticus case with multiple cranial nerves involvement and discussed with literature.

Key Words: Herpes Zoster Oticus, geniculate ganglion, polycranial neuronitis.

Turk Arch Otolaryngol, 2012; 50(3):54-56

Introduction

Herpes Zoster Oticus (HZO), multiple herpes bullas around ear, is a viral infection caused by varicella zoster virus (VZV) and mostly combined with loss of hearing and balance disorder. Herpes zoster occurs with the activation of the virus which stayed latent at sensory ganglions after the occurrence of a chicken pox infection earlier time. It can lead to infection through dermatome or in one or more trace of cranial nerves.^{1,2} Palsy begins with pain and burning sensation. Mostly 1-4 days after the beginning of the pain, vesicular rashes are observed often in the concha and eksternal ear channel postero-lateral part, or less often on face, neck, and mouth. Rashes start as red, vesicular and papules that are able to show crusting. Resolution occurs in 10-14 days. V, VII, IX, X, and XII. cranial nerves and all fibers containing cervical plexus arising from cervical II, III, and IV can be paralyzed. Headache, fatigue and fever may accompany to these symptoms. We here present a HZO case with multiple cranial nerves involvement treated with acyclovir. Efficacy of oral acyclovir treatment in patients` with HZO was evaluated by clinical observation.

Alper Yenigün, MD

Clinic of Otorbinolaryngology, Karaman State Hospital, Karaman

M. Fatih Evcimik, MD

Clinic of Otorbinolaryngology, İstanbul Nisa Hospital, İstanbul

H.Deniz Tansuker, MD

Clinic of Otorbinolaryngology, Devrek State Hospital, Zonguldak

Ö. Faruk Çalım, MD

Department of Otorbinolaryngology, Medipol University Hospital, İstanbul

Case Report

Sixty-two years old male patient referred to our clinics with complains of eruption on his right ear channel and ear pinna, ear pain, pain and burning sensation on tongue tip and under the tongue, numbness and taste sense decrease on the right side of tongue, and numbness at the right side of the face.

Patient's history indicated that all complains started five days ago. Past medical history revealed untreated chickenpox infection at the age of 62 and suffering chronic otitis media for almost 15 years with several treatment attempts. Physical examination showed moderate overall condition, vesicular skin eruptions on the right auricula, external ear canal, preauricular region and right side of face (Figure 1, 2). Numbness, decreased taste sensation and movement restrictions on the right side of tongue have been detected. A painful, hyperemic and erythematous lesion progress along with the trace of nervus lingualis which does not cross middle line was observed on the right half of tongue (Figure 2). Physical examination of cranial nerves suggested involvement of lingual branch of 7th cranial nerve due to sensory numbness on the tongue and involvement of 12th cranial nerve due to numbness on motor movements. Otoscopic examination showed bilateral perforation in central portion of tympanic membranes. Facial paralysis is evaluated as

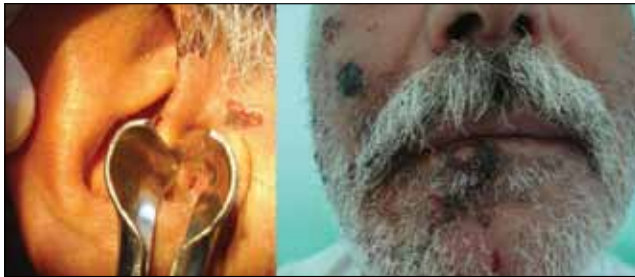

Figure 1. Vesicular skin eruptions on the right auricula, external ear canal and the patient's face before therapy.

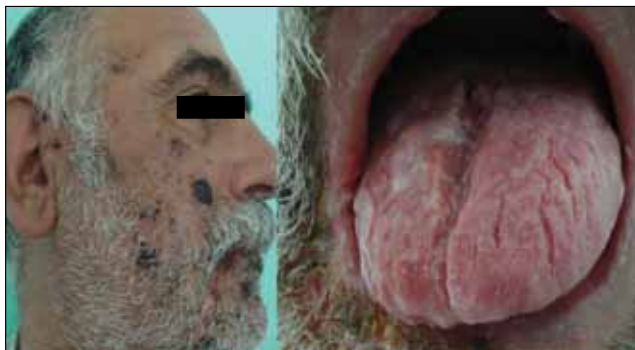

Figure 2. Preauricular region and right side of face, hyperemic and erythematous lesion on the right half of tongue before therapy.

House-Brackmann phase-II. Pure tone audiogram indicated that there was 40 dB sensorineural hearing loss in patient's right ear (Figure 3). Hearing loss suggested involvement of cochlear branch of 8th cranial nerve.

Based on clinical appearance and medical history, the patient was diagnosed with herpes zoster oticus, and 400 mg of oral acyclovir to be taken as 5 times daily for 14 days was given to patient. Also, aklovir pomade was given for skin lesions. One week after the initiation of therapy ear pain and vesicles disappeared and other skin lesions completely disappeared by the end of two weeks of treatment (Figure 4). These findings are evaluated as extramedullary manifestations of meningovascular inflammation. Demyelination in cranial nerves suggested disseminated infection. Although exact mechanism of such kind of dissemination is not known, it is thought that reaction due to meningitis results in perineural direct viral dissemination via anastomosis or regional meningitis leads to multiple cranial nerve involvement. Anastomosis between 5, 7, 9 and 10th cranial nerves explains the findings in these nerves. Furthermore, relations between cranial nerves in cavernous sinus support the theory of multiple cranial nerve involvement in HZO.

Discussion

Lower cranial nerve involvement in Herpes Zoster Oticus is very rare condition and two cases have been reported up to date, Nishioka et al. showed the thinning of myelin layer in cranial nerves and proposed as underlying mechanism in disseminated cranial nerve involvement.³ Also, pleositoz (increase of lymphocytes in the cerebrospinal fluid) and increased amount of protein in CSF have been observed in BOS examination in these cases. These findings are evaluated as extramedullary manifestations of meningovascular system inflammation. It was thought that dissemination of infection was correlated with the loss of myelin at cranial nerves. Although the exact mechanism of this dissemination is unknown, it was thought that multiple cranial nerve involvement was caused by meningitis-related reactions, spread of infection to perineural through regional meningitis or anastomoz. Occurrence of anastomosis between 5, 7, 9 and 10th cranial nerves also explains why the symptoms occurs in these nerves. In addition, cranial nerves neighborhood within the cavernous sinus supports the theory for HZO multiple cranial nerve involvement.⁴ The other theory proposed for unilateral involvement is HZO disseminate in the form of vasculitis and cause inflammation at multiple cranial nerves when cranial nerves are distributed according to vascularization.⁵ While 3-6 cranial nerves feed from intracavernous internal carotid artery, the face

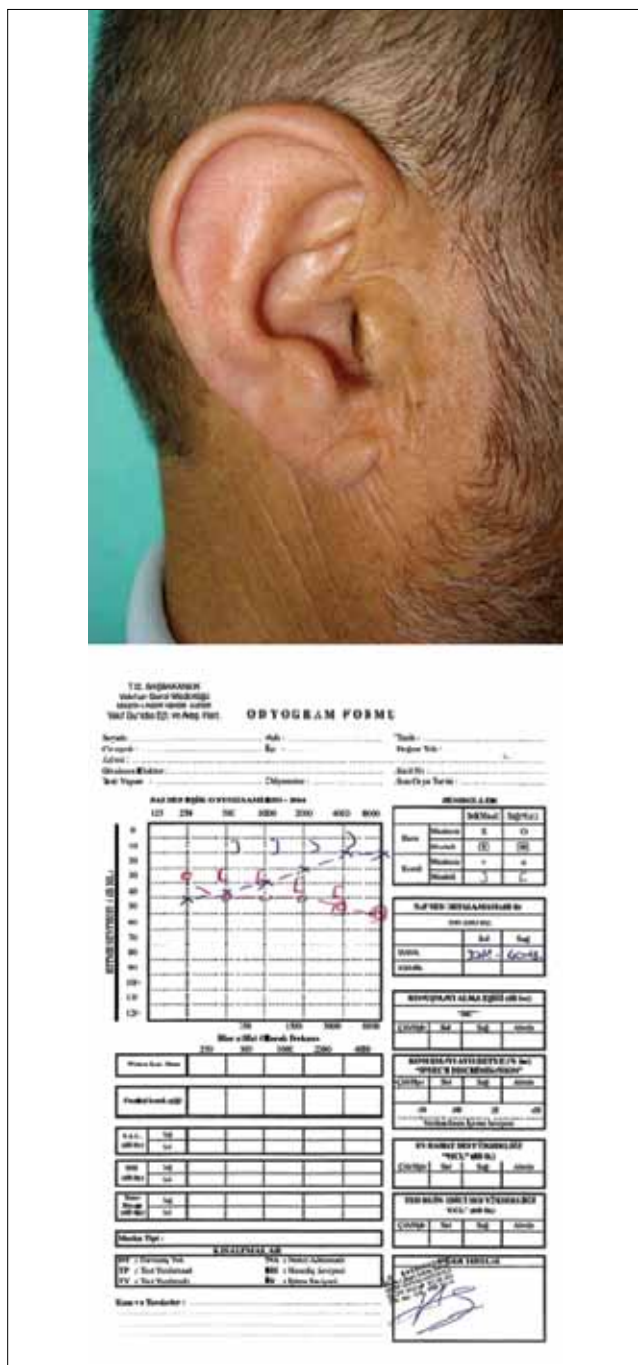


Figure 3. Right auricula and right external ear canal after therapy.

nerves and the second and third branches of the trigeminal nerve feed from the middle meningeal artery. 9-12th cranial nerves feed from the ascending pharyngeal artery. Lapresle and Faux have reported continuously and severely effected cervical herpes zoster (C2-C4) cases involving 9-12th cranial nerves and angiography showed

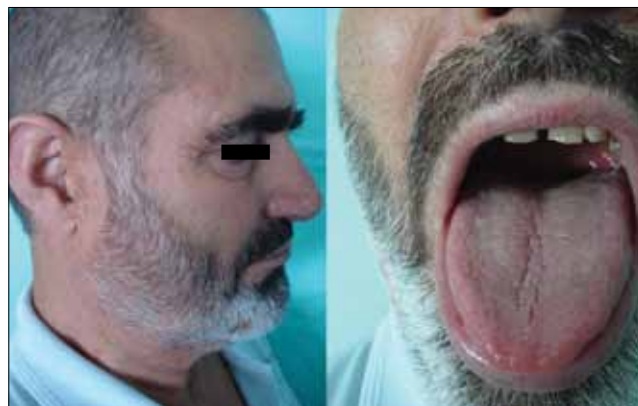

Figure 4. Right face and tongue after therapy.

occlusion in ascending pharyngeal artery which supports vasculitis theory.⁶ Malign infiltration has to be considered in unilaterally effected patients who are irresponsive to therapy (Garcin send). Also, if there is a suspicious clinical diagnosis with polyneuropathy, one can consider checking antibodies for VZV.

In conclusion, Multiple cranial nerve involvement has been observed in patients who are referred with the HZO preliminary diagnosis. Those patients have to be examined in detail for their cranial nerve involvement. Early diagnosis and treatment is important for reversing the functions of cranial nerves in HZO cases.

References

1. **Balkany TJ, Ress BD.** Infections of the external ear, Cummings CW, Fredrickson JM, Harker LA, Krause CJ, Richardson MA, Schuller DE (Eds) : Otolaryngology Head and Neck Surgery. Third edition, Mosby Year Book Inc., St.Louis: 1998, s.2979-86.
2. **Kinishi M, Amatsu M, Mohri M, Saito M, Hasegawa T, Hasegawa S.** Acyclovir improves recovery rate of facial nerve palsy in Ramsay Hunt syndrome., *Auris Nasus Larynx* 2001; 28: 223-6.
3. **Nishioka K, Fujishima K, Kobayashi H, Mizuno Y, Okuma Y.** An extremely unusual presentation of varicella zoster viral infection of cranial nerves mimicking Garcin syndrome. *Clin Neurol Neurosurg* 2006; 108: 772-4.
4. **Ohashi T, Fujimoto M, Shimizu H, Atsumi T.** A case of isolated vagus nerve palsy with herpes zoster. *Rinsho Shinkeigaku* 1994; 34: 928-9.
5. **Nishizaki K, Onoda K, Akagi H, Yuen K, Ogawa T, Masuda Y.** Laryngeal zoster with unilateral laryngeal paralysis. *ORL J Otorhinolaryngol Relat Spec* 1997; 59: 235-7.
6. **Lapresle J, Faux N.** [Unilateral involvement of IX, X, XI and XII in cervical zoster. Cranial nerve contribution to vascular pathology]. *J Neurol Sci* 1981; 52: 351-7.

Conflict of interest statement:

No conflicts declared.

Corresponding Author: Alper Yenigün, MD

Clinic of Otorhinolaryngology, Karaman State Hospital, Turgut Özal Street No: 1 KARAMAN
Phone: +90 505 504 06 96
Fax: +90 338 226 33 09
e-mail: alperyenigun@gmail.com