



RESEARCH ARTICLE

The expression profiles of NF- κ B, Hsp70, and TNF- α in swine urinary bladder: an immunohistochemical study

Tuğrul Ertuğrul^{1*}, Ahmet Ceylan²

¹Ondokuz Mayıs University, Veterinary Faculty, Department of Histology and Embryology, Samsun, Turkey
²Ankara University, Veterinary Faculty, Department of Histology and Embryology, Ankara, Turkey

Received:29.09.2021, Accepted: 13.01.2022
*tugrulertugrul06@hotmail.com

Domuz idrar kesesinde NF- κ B, Hsp70 ve TNF- α 'nın ekspresyon profilleri: immünohistokimyasal bir çalışma

Eurasian J Vet Sci, 2022, 38, 1, 1-6
DOI: 10.15312/EurasianJVetSci.2022.358

Öz

Amaç: Bu çalışmada domuz idrar kesesinde immünohistokimyasal olarak NF- κ B, Hsp70 ve TNF- α ekspresyonunu araştırmayı amaçladık.

Gereç ve Yöntem: Çalışmada materyal olarak toplam 8 adet domuz idrar kesesi kullanıldı. NF- κ B, Hsp70 ve TNF- α ekspresyonu Streptavidin-biotin kompleks immünohistokimya yöntemini ile gösterildi.

Bulgular: Üroepitelyal hücreler NF- κ B ile fokal sitoplazmik reaksiyon verdi. Detrusor kas katmanının düz kas hücrelerinde ve damar duvarında orta derecede NF- κ B boyanma yoğunluğu gözlemlendi. Bazal ve intermediyer hücrelerin sitoplazmalarında ve çekirdeklerinde Hsp70 ekspresyonu gözlemlendi. Bazal hücre çekirdeklerinin güçlü bir reaksiyon göstermesi dikkat çekiciydi. İdrar kesesinin düz kas demetleri, Hsp70 ile pozitif olarak boyandı. TNF- α ekspresyonu, idrar kesesinde kahverengi olarak ürotelyumun üç tabakasının tamamında gözlemlendi. İlginç bir şekilde, bazı şemsiye hücrelerin lümen yüzeylerinin yoğun membran benzeri immünopozitif boyama gösterdiğini belirledik.

Öneri: Bu çalışmada, domuz idrar kesesinde NF- κ B, Hsp70 ve TNF- α ekspresyonu tunika mukozanın epitel hücrelerinde ve tunika muscularisin düz kas hücrelerinde belirlendi. İmmünohistokimyasal bulgulara dayanarak, ürotelyum ve detrusor kas tabakasını oluşturan hücreler tarafından salgılanan enzimlerin ve sitokinlerin biyolojik süreç, hücreler arası iletişime, fizyolojik duruma katkıda bulunduğu ve idrar kesesinin savunmasında önemli bir rol oynadığı sonucuna varıldı.

Anahtar kelimeler: İdrar kesesi, NF- κ B, Hsp70, TNF- α

Abstract

Aim: This study aimed to investigate the expression of NF- κ B, Hsp70, and TNF- α immunohistochemically in the swine urinary bladder.

Materials and Methods: A total of 8 swine urinary bladders were used as material in the study. NF- κ B, Hsp70 and TNF- α expression were demonstrated by Streptavidin-biotin complex immunohistochemistry method.

Results: Uroepithelial cells gave a focal cytoplasmic reaction with NF- κ B. A moderate staining intensity was observed in NF- κ B, smooth muscle cells of the detrusor muscle layer and in the vessel wall. Hsp70 expression was observed in the cytoplasm and nuclei of basal and intermediate cells. It was remarkable that basal cell nuclei showed a strong reaction. The bladder's smooth muscle bundles were stained positively with Hsp70. TNF- α expression was observed throughout all three layers of urothelium as a brown color in the urinary bladder. Interestingly, we determined that some umbrella cells' luminal surfaces showed intense membrane-like immunopositive staining.

Conclusion: In this study, the expression of NF- κ B, Hsp70, and TNF- α in the swine urinary bladder was determined in epithelial cells of tunika mucosa and smooth muscle cells of tunika muscularis. Based on the immunohistochemical findings, it was concluded that the enzymes and cytokines secreted by the cells forming the urothelium and detrusor muscle layer contribute to the biological process, intercellular communication, physiological state and play an important role in defense of the urinary bladder.

Keywords: Urinary bladder, NF- κ B, Hsp70, TNF- α



Introduction

The urinary bladder is a multilayered structure characterized by the major layers of tunica mucosa, tunica muscularis, and tunica serosa (Samuelson 2007). The tunica muscularis consists of strong smooth muscle cells. This layer is also called the "detrusor muscle." The urothelium (uroepithelium), the epithelial lining of the urinary bladder, is a highly specialized epithelium (Ertuğrul and Kurtdeğir 2013). It composed at least three layers: a basal cell layer attached to the basal membrane, an intermediate layer, and a superficial cell layer known as an "umbrella cell" (Birder 2005). The primary role of uroepithelium is to provide a barrier that prevents pathogen entry and selectively regulates the passage of water, ions, solutes, and large macromolecules through the mucosal surface of the cell into the underlying tissue (Apodaca 2004). In response to possible foreign substances, urothelium may release cytokines, growth factors, and other inflammatory mediators (Wood et al 2011).

Nuclear factor-kappa B (NF- κ B), a protein transcription factor (Liu et al 2017), is considered a regulator of innate immunity (Baltimore 2009). NF- κ B's signaling pathways regulate cellular resistance against invading pathogens (Karin 2009) and control the expression of various pro-inflammatory cytokines and acute-phase proteins (Liu et al 2017). Heat shock proteins (Hsps) are critically important for cellular development and viability in many organisms (Zou et al 2012). They play a role in various biological activities, such as protection against apoptosis and cytotoxic damage (Rokuten 2000). HSPs in cells support the right folding of proteins, refolding of misfolded proteins, and degradation of irrecoverable proteins to maintain the cytoskeleton structure (Garrido et al 2001). Hsp70 is a type of molecular chaperone that is activated in response to a variety of cellular stresses. It protect proteins from degradation by stabilizing them (Morimoto 1993). Tumor necrosis factor-alpha (TNF- α), which is a cytokine with proinflammatory and immunostimulating effects (Wang et al 2003), is effective in angiogenesis, inflammation, and cell proliferation (Boric et al 2013). TNF- α regulates the immune response to pathogenic agents and has a chemotactic effect on monocyte and polymorphonuclear leukocytes (Maury and Teppo 1989). Furthermore, studies show that TNF- α can directly stimulate detrusor muscle smooth muscle cell contraction in the urinary bladder (Wang et al 2012).

Cytokine expression may form a bi-directional communication network of the neurological and the immune systems, alone or with other cytokines, growth factors, or other mediators (Watkins and Maier 1999). The study's objective is to determine the distribution of NF- κ B, Hsp70, and TNF- α expression immunohistochemically in swine urinary bladder.

Material and Methods

Materials

The study used fresh urine bladder samples from eight one-month-old healthy swine as material. The samples were collected from Ankara University Faculty of Veterinary Medicine Application and Research Farm.

Tissue processing

The urinary bladder tissue samples were fixed in a 10% formaldehyde solution for 24 hours. The tissues were held for 1 hour in each of 70 percent, 80 percent, and 96 percent alcohol after being stored in a running water bath for 24 hours to remove the formalin. This was followed by three 1 hour applications of absolute alcohol and xylol were done. The tissue samples were then blocked in paraffin.

Immunohistochemistry

The urinary bladder sections 5 μ m thick taken from paraffin blocks were stained immunohistochemically by using rabbit polyclonal Hsp70 (1/200 dilution, Santa Cruz Biotechnology, sc-33575), mouse monoclonal NF- κ B (1/200 dilution, Santa Cruz Biotechnology, sc-8008) and rabbit polyclonal TNF- α (1/200 dilution, Abcam, AB-9739) primary antibodies with Streptavidin biotin complex (True 1990). Histostain Plus (Zymed kit: 85-6743) kit was performed as secondary antibody. After deparaffinization, sections were heated in a microwave oven of 700 watts within citrate buffer (pH=6) solution for proteolysis. In order to block endogenous peroxidase activity, the tissues were incubated in 3% hydrogen peroxide solution. Following washing with phosphate buffer solution (PBS), serum in the kit was instilled to prevent nonspecific protein binding in sections. Primary antibody was applied on and they were stored at +4 °C for overnight. Only PBS solution was process on negative control group tissues. Following the washing procedure, biotinylated secondary antibody was instilled into sections and incubated at streptavidin-horse-radish peroxidase complex after washing. As the last stage, 3, 3'-diaminobenzidine (DAB) was used as chromogen and the preparations were covered with entellan by counterstaining was performed with hematoxylin.

Immunohistochemical examination

Following immunohistochemical staining, the NF- κ B, Hsp70, and TNF- α staining intensity was assigned a semiquantitative score using a light microscope (Nikon Eclipse 50i): negative (-), weak reaction (+), moderate reaction (++) and strong reaction (+++) (Özen et al 2013).

Table 1. Semiquantitative scoring of staining intensities for NF- κ B, Hsp70, and TNF- α in swine urinary bladder

			NF- κ B	Hsp70	TNF- α
Urothelium	Superficial cell	cytoplasm	+	-	++
		nucleus	-	-	-
	Intermediate cell	cytoplasm	+	++	++
		nucleus	-	-	-
Blood vessels	Basal cell	cytoplasm	+	+	++
		nucleus	-	+++	-
		cytoplasm	++	++	++
		nucleus	-	+++	-
Detrusor muscle		cytoplasm	++	++	++
		nucleus	-	+++	-

Semiquantitative scoring of immunostaining intensities: -, negative; +, weak; ++, moderate; +++, strong.

Results

Immunohistochemical results were evaluated and summarized in Table 1.

In sections stained by NF- κ B, uroepithelial cells gave focal cytoplasmic staining. Membrane-like immunopositive staining was predominantly observed on the lateral surface of epithelial cells. A moderate staining intensity was observed in NF- κ B, smooth muscle cells of the detrusor layer and in the vessel wall. The nuclei of the cells in the uroepithelium, tunica muscularis, and blood vessels were not stained (Figure 1).

In sections stained by Hsp70, umbrella cell cytoplasm and nuclei did not give positivity. Only the cell membrane of the umbrella cell was stained. Hsp70 expression was observed in the cytoplasm and nuclei of basal and intermediate cells.

It was remarkable that basal cell nuclei showed a strong reaction. The bladder's smooth muscle bundles were stained positively with anti-Hsp70. The reaction observed in the cytoplasm of smooth muscle was weaker than that observed in the nuclei of smooth muscle. Also, Hsp70 expression was strong in blood vessels (Figure 2).

TNF- α expression was observed throughout all three layers of urothelium as a brown color in the urinary bladder. Membrane-like and intracytoplasmically immunopositive staining were determined epithelial cells. Interestingly, we determined that some umbrella cells' luminal surfaces showed intense membrane-like immunopositive staining. TNF- α was observed in a moderate stain on the smooth muscle of the detrusor muscle and vessels wall. The nuclei were not stained in the tunica muscularis, blood vessels, and uroepithelium (Figure 3).

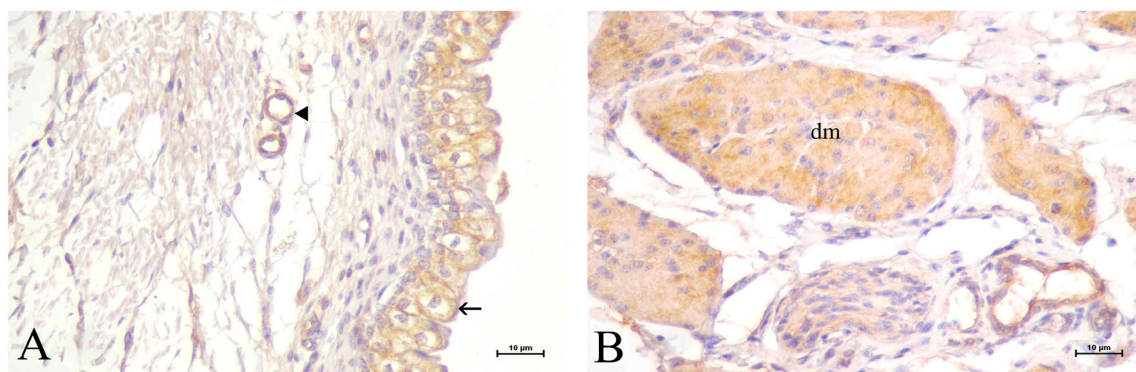


Figure 1. (A) NF- κ B expression in the urothelium, umbrella cell (arrow), blood vessel (arrow head). (B) Moderate NF- κ B expression in the detrusor muscle (dm). Bar: 10 μ m

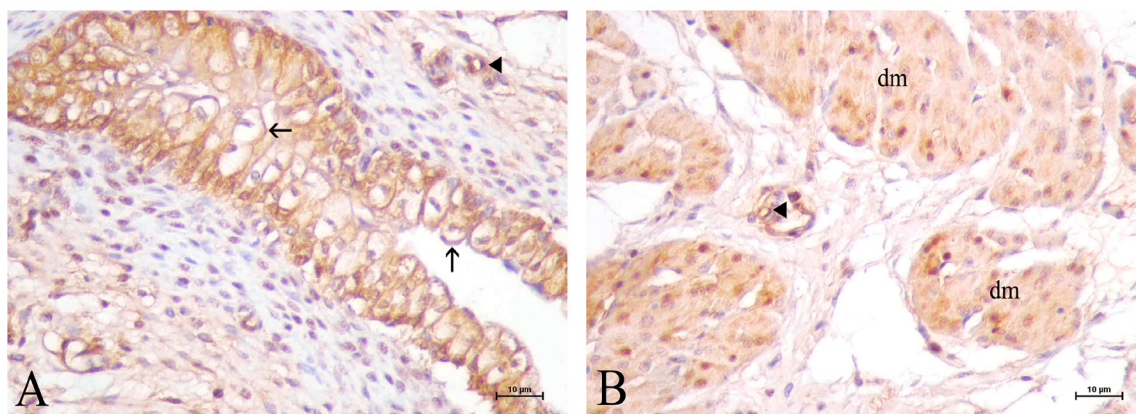


Figure 2. (A) Hsp70 expression in the urothelium, umbrella cell (arrows), blood vessel (arrow heads). (B) moderate Hsp 70 expression in the detrusor muscle (dm), blood vessels (arrow heads). Bar: 10 μ m

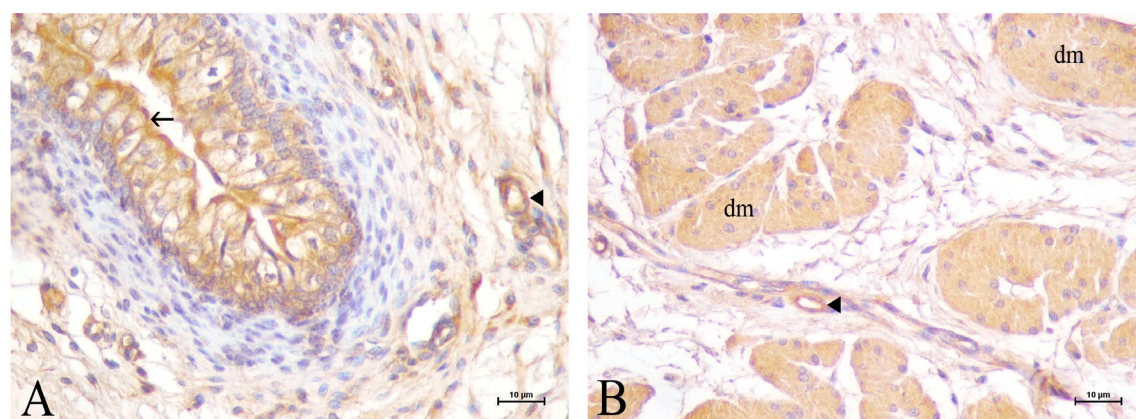


Figure 3. (A) Luminal surface membrane immunopositivity TNF- α in umbrella cell (arrow). (B) TNF- α expression in the detrusor muscle (dm), blood vessels (arrow heads). Bar: 10 μ m

Discussion

The urinary bladder mucosal defense protects against foreign substances, both by their morphological structure and induced factors. The urothelium, a unique stratified epithelium that lines the lower urinary tract, acts as a permeability barrier and a barrier against bacterial adhesion and invasion (Wu et al 2009). Because the urinary system is frequently exposed to microorganisms, an arsenal of both structural and triggered, innate defense systems has evolved (O'Brien et al 2015). Pattern recognition receptor signaling in the bladder wall and urothelium activates urothelial and bladder resident immune cells and coordinated cytokine and chemokine secretion (Duell et al 2012).

NF- κ B is involved in a wide variety of physiological processes such as immunity, cell proliferation/differentiation. It also plays an important role in inflammation (Zhang et al 2017).

NF- κ B is involved in mediating the innate immune system and regulating T and B cells' autoimmune and inflammatory functions (Sun et al 2013). The urothelium's barrier integrity can be regulated directly or indirectly by NF- κ B, regulating cell adhesion molecules like E-cadherin (Krischak et al 2021). The umbrella, intermediate, and basal cells forming the urothelium were stained intracytoplasmically with NF- κ B in a study performed in the rat urinary bladder (Yucel et al 2013). Previous studies have shown that NF- κ B can be activated by bacterial and viral infections, inflammatory cytokines, ischemia, hyperosmotic shock, and oxidative stress (Baeuerle and Henkel 1994). NF- κ B mediates multiple stages of bladder inflammation (Abdel-Mageed and Ghoniem 1998). In a study of patients with interstitial cystitis, it was observed that NF- κ B expression, which was detected weakly in the cytoplasm of urothelial cells in the control group, was increased cystitis group (Wang et al 2000). This study demonstrated the expression of the NF- κ B in the swine uri-



nary bladder. The presence of immunoreactivity in urothelial cells, the detrusor muscle, and blood vessels suggests that NF- κ B, which is involved in various physiological processes, including immunity and cell proliferation, may an essential role in the urine bladder.

Hsp's are expressed and controlled through hormones during normal cellular growth, mitosis, and differentiation (Verbeke et al 2001). Hsp's appear to play a role in various biological processes, including apoptosis resistance, carcinogenesis, and cytotoxic damage. Under environmental, physiological, and pathophysiological stress, Hsp synthesis is highly regulated, resulting in increased synthesis, particularly of the Hsp70 (Qu et al 2015). The presence of Hsp70 in the bladder's detrusor muscle and mucosal epithelium was demonstrated by immunohistochemical in rabbit urinary bladder (Zhao et al 1993). In addition, Syrigos et al. (2003) reported having observed positive immune reactions for Hsp70 in the cytoplasm and cell membrane of uroepithelium of the urinary bladder in humans. The cytoplasm, cell membranes, and nucleus of urothelial cells and detrusor smooth muscle cells showed a positive reaction to Hsp70 in our research. Our findings are consistent with the findings of the researchers. The expression of Hsp 70, which is known to contribute to the sequencing of proteins involved in the cytoskeletal network, suggests that it plays an influential role in the filling and emptying mechanism of the urinary bladder, where the cells undergo physical changes.

Cytokine expression, growth factors, or other mediators can form a bidirectional communication network between the nervous and immune systems (Watkins and Maier 1999). Cytokines, including TNF- α , are regulatory proteins released by various cells and promote intercellular communication and immune responses (Jia et al 2015). In the urinary bladder, studies suggested that TNF- α primarily induces urothelial apoptosis via the TNF-related apoptosis-inducing ligand (TRAIL) pathway (Kutlu et al 2010). The study in TNF- α deficient mice showed that following infection, neutrophils require local TNF- α signaling to cross the basement membrane of the urinary bladder epithelium (Schiwon al 2014). Experimental results show that in the urinary bladder TNF- α is predominantly expressed in the urothelium (Giglio et al 2016). Wang et al. (2012) reported that TNF- α was can directly stimulate bladder smooth muscle cell contraction. Positive staining was found in the urothelium, smooth muscle cells of the tunica muscularis, and the vessel wall in our research. TNF- α 's ability to regulate immune cells and induce a wide range of cellular responses in various target cells, including inflammation, cell proliferation, differentiation, and apoptosis, suggests that it is an important cytokine in the urinary bladder's defense mechanism.

Conclusion

As a result, in this study, it was observed that the swine urinary bladder displayed the expression of NF- κ B, Hsp70, and TNF- α . Based on the immunohistochemical findings, it was concluded that the enzymes and cytokines secreted by the cells forming the urothelium and detrusor muscle layer contribute to the biological process, intercellular communication, physiological state, and play an essential role in the defense of the urinary bladder.

Conflict of Interest

The authors did not report any conflict of interest or financial support.

Funding

During this study, any pharmaceutical company which has a direct connection with the research subject, a company that provides and / or manufactures medical instruments, equipment and materials or any commercial company may have a negative impact on the decision to be made during the evaluation process of the study or no moral support.

References

- Abdel-Mageed AB, Ghoniem GM, 1998. Potential role of rel/ nuclear factor-kappaB in the pathogenesis of interstitial cystitis. *J Urol*, 160(6), 2000-3.
- Apodaca G, 2004. The Uroepithelium: Not Just a Passive Barrier. *Traffic*, 5(3), 117-28.
- Baeuerle P, Henkel T, 1994. Function and activation of NF-kappa B in the immune system. *Annu Rev Immunol*, 12, 141-79.
- Baltimore D, 2009. Discovering NF- κ B. *Cold Spring Harb Perspect Biol*, 1 (1), a000026.
- Birder LA, 2005. More than just a barrier: urothelium as a drug target for urinary bladder pain. *Am J Physiol*, 289, 489-95.
- Boric MA, Torres M, Pinto C, Pino M, et al., 2013. TNF system in eutopic endometrium from women with endometriosis. *OJOG*, 3, 271-78.
- Duell BL, Carey AJ, Tan CK, Cui X, et al., 2012. Innate transcriptional networks activated in bladder in response to uropathogenic *Escherichia coli* drive diverse biological pathways and rapid synthesis of IL-10 for defense against bacterial urinary tract infection. *J Immunol*, 188, 781-92.
- Ertuğrul T, Kurtdele N, 2013. Transitional Epithelium. *Atatürk Üniversitesi Vet Bil Derg*, 8(3), 241-47.
- Garrido C, Gurbuxani S, Ravagnan L, Kroemer G, 2001. Heat shock proteins: endogenous modulators of apoptotic cell death. *Biochem Biophys Res Commun*, 286, 433-442.
- Giglio D, Wasén C, Mölne J, Suchy D, et al., 2016. Downregula-





- tion of toll-like receptor 4 and IL-6 following irradiation of the rat urinary bladder. *Clin Exp Pharmacol Physiol*, 43(7), 698-705.
- Jia, Y, Liu, X, Yan J, Chong L, et al., 2015. The alteration of inflammatory markers and apoptosis on chronic prostatitis induced by estrogen and androgen. *Int Urol Nephrol*, 47(1), 39-46.
- Karin M, 2009. NF- κ B as a critical link between inflammation and cancer. *Cold Spring Harb Perspect Biol*, 1 (5), a000141.
- Krischak A, Kowaliuk J, Sarsarshahi S, Dörr W, 2021. Effect of irradiation on the expression of E-cadherin and β -catenin in early and late radiation sequelae of the urinary bladder and its modulation by NF- κ B inhibitor thalidomide. *Strahlenther Onkol*, 97(6), 537-46.
- Kutlu O, Akkaya E, Koksall IT, Bassorgun IC, et al., 2010. Importance of TNF-related apoptosis-inducing ligand in pathogenesis of interstitial cystitis. *Int Urol Nephrol*, 42(2), 393-9.
- Liu T, Zhang L, Joo D, Sun SC, 2017. NF- κ B signaling in inflammation. *Signal Transduct Target Ther*, 2 (1), 1-9.
- Maury CPJ, Teppo AM, 1989. Circulating tumor necrosis factor-alpha (cachectin) in myocardial infarction. *J Int Med*, 225, 333-36.
- Morimoto RI, 1993. Cells in stress: transcriptional activation of heat shock genes. *Science* 259:1409.
- O'Brien VP, Hannan TJ, Schaeffer AJ, Hultgren SJ. 2015. Are you experienced? Understanding bladder innate immunity in the context of recurrent urinary tract infection. *Curr Opin Infect Dis*, 28(1), 97-105.
- Özen A, Ergün E, Öztas E, Ergün L, et al., 2013. Immunohistochemical expression of nitric oxide synthase enzymes (iNOS, eNOS, nNOS) in the estrual and luteal phases of the sexual cycle in the cow oviduct. *Anatomia, Histologia, Embryologia*, 42(5), 384-93.
- Qu B, Jia Y, Liu Y, Wang H, et al., 2015. The detection and role of heat shock protein 70 in various nondisease conditions and disease conditions: a literature review. *Cell Stress and Chaperones*, 20(6), 885-92.
- Rokutan K, 2000. Role of heat shock proteins in gastric mucosal protection. *J Gastroenterol Hepatol*, 15, 12-19.
- Samuelson DA, 2007. *Textbook of Veterinary Histology*. Saunders Elsevier, China, pp; 78-80.
- Schiwon M, Weisheit C, Franken L, Gutweiler S, et al., 2014. Crosstalk between sentinel and helper macrophages permits neutrophil migration into infected uroepithelium. *Cell*, 156(3), 456-68.
- Sun SC, Chang JH, Jin J, 2013. Regulation of nuclear factor-kappaB in autoimmunity. *Trends Immunol*, 34 (6), 282-9.
- Syrgios KN, Harrington KJ, Karayiannakis AJ, Sekara E, et al., 2003. Clinical significance of heat shock protein-70 expression in bladder cancer. *Urology*. 61(3), 677-80.
- True LD, 1990. *Principles of immunohistochemistry*. Gower Medical Publishing, New York.
- Verbeke P, Fonager J, Clark BF, Rattan SI, 2001. Heat shock response and ageing: mechanisms and applications. *Cell Biol Int*, 25(9), 845-57.
- Watkins LR, Maier SF, 1999. Implications of immune-to-brain communication for sickness and pain. *Proc Natl Acad Sci U S A*, 96(14), 7710-13.
- Wang XC, Saban R, Kaysen JH, Saban MR, et al., 2000. Nuclear factor kappa B mediates lipopolysaccharide-induced inflammation in the urinary bladder. *J Urol*, 163(3), 993-98.
- Wang H, Czura CJ, Tracey KJ, Angus WT, et al., 2003. Tumor Necrosis Factor. *The Cytokine Handbook*, Fourth edition, Academic Press, London, pp; 837-860.
- Wang Z, Cheng Z, Cristofaro V, Li J, et al., 2012. Inhibition of TNF- α improves the bladder dysfunction that is associated with type 2 diabetes. *Diabetes*, 61(8), 2134-45.
- Wood MW, Breitschwerdt EB, Gookin JL, 2011. Autocrine effects of interleukin-6 mediate acute-phase proinflammatory and tissue-reparative transcriptional responses of canine bladder mucosa. *Infect Immun*, 79(2), 708-15.
- Wu XR, Kong XP, Pellicer A, Kreibich G et al., 2009. Uroplakins in urothelial biology, function, and disease. *Kidney Int*, 75, 1153-65.
- Yucel M, Kucuk A, Bayraktar AC, Tosun M, 2013. Protective effects of the nuclear factor kappa B inhibitor pyrrolidine dithiocarbamate in bladder ischemia-reperfusion injury in rats. *Mol Biol Rep*, 40(10), 5733-40.
- Zhang Q, Lenardo MJ, Baltimore D, 2017. 30 years of NF- κ B: a blossoming of relevance to human pathobiology. *Cell*, 168, 37-57.
- Zhao Y, Levin RM, Monson FC, Chacko S, 1993. Expression of constitutive heat shock protein-70 in normal (non-stressed) rabbit urinary bladder tissue. *Molecular and Cellular Biochemistry*. 121, 13-19.
- Zou J, Liu C, Liu A, Zou D, et al., 2012. Overexpression of OsHsp17.0 and OsHsp23.7 enhances drought and salt tolerance in rice. *J Plant Physiol*, 169 (6), 628-35.

Author Contributions

Motivation / Concept: Tuğrul Ertuğrul
Design: Tuğrul Ertuğrul
Control/Supervision: Tuğrul Ertuğrul, Ahmet Ceylan
Data Collection and / or Processing: Tuğrul Ertuğrul, Ahmet Ceylan
Analysis and / or Interpretation: Tuğrul Ertuğrul
Literature Review: Tuğrul Ertuğrul
Writing the Article: Tuğrul Ertuğrul, Ahmet Ceylan
Critical Review: Tuğrul Ertuğrul, Ahmet Ceylan

Ethical Approval

Approval of the study was obtained from Ankara University, Animal Experiments Local Ethics Committee (2012-1/2012-4/2012-1-5) Number Ethics Committee Decision.

CITE THIS ARTICLE: Ertuğrul T, Ceylan A, 2022. The expression profiles of NF- κ B, Hsp70, and TNF- α in swine urinary bladder: an immunohistochemical study. *Eurasian J Vet Sci*, 38, 1, 1-6.

